

**A TUTORIAL ON REPOSITIONING MANEUVERS FOR BENIGN  
PAROXYSMAL POSITIONAL VERTIGO**

Shradha Manandhar

**Register No.: 19AUD036**

A Dissertation Submitted in Part Fulfillment of Degree of Master of Science

(Audiology)

University of Mysore

Mysuru



**ALL INDIA INSTITUTE OF SPEECH AND HEARING**

**MANASAGANGOTHRI, MYSURU-570 006**

**SEPTEMBER, 2021**

## **CERTIFICATE**

This is to certify that this dissertation entitled “**A tutorial on repositioning maneuvers for benign paroxysmal positional vertigo**” is a bonafide work submitted in part fulfillment for the degree of Master of Science (Audiology) of the student with Registration Number 19AUD036. This has been carried out under the guidance of the faculty of this institute and has not been submitted earlier to any other University for the award of any other Diploma or Degree.

Mysuru

September, 2021

**Dr. M. Pushpavathi**

**Director**

All India Institute of Speech and Hearing

Manasagangothri, Mysuru-570006

## **CERTIFICATE**

This is to certify that this dissertation entitled “**A tutorial on repositioning maneuvers for benign paroxysmal positional vertigo**” has been prepared under my supervision and guidance. It is also certified that this dissertation has not been submitted earlier to any other University for the award of any other Diploma or Degree.

Mysuru  
September, 2021

**Guide**  
**Dr. Sujeet Kumar Sinha**  
Associate Professor  
Department of Audiology  
All India Institute of Speech and Hearing  
Manasagangothri, Mysuru-570006

## **DECLARATION**

This is to certify that this dissertation entitled “**A tutorial on repositioning maneuvers for benign paroxysmal positional vertigo**” is the result of my own study under the guidance of Dr. Sujeet Kumar Sinha, Associate Professor, Department of Audiology, All India Institute of Speech and Hearing, Mysuru, and has not been submitted earlier to any other University for the award of any other Diploma or Degree.

Mysuru,

**Registration No: 19AUD036**

September, 2021

## ACKNOWLEDGEMENT

*I thank the almighty God for the blessings you have bestowed upon me and for the wonderful opportunities you have given.*

*Sujeet sir, thankyou for the guidance, the opportunity and the knowledge you have given me. You have always inspired me sir. I sincerely thank you for being so patient and kind with me, and guiding me through all the work.*

*Thankyou to the current director Dr. Pushpavathi ma'am and HOD Audiology Dr. Prawin sir for this opportunity. Thankyou to all the faculty members of the institute. I would also like to thank Animesh sir, Niraj sir, Sandeep sir and Prashanth sir for being such amazing teachers and inspiring me.*

*Mamu thankyou for everything you have done for me, for always being there, for going out of your way to support me, for teaching me to live on my own terms and for the unconditional love. Daddy thankyou for all your love and support, for always encouraging and believing in me. Shreya you are my perfect little sister, my personal entertainer and partner in crime, I am blessed to have you. Ba, ma, mummyma and baa I will always cherish all the wonderful memories with you.*

*To my extended family, Rajesh thuldaddy, Nidhu mama, Deepak thuldaddy, Bina aunty, Anu aunty, Chandika thulmummy, Ambu thulmummy, Manu thulmummy, and all my cousins, you guys have always thought the best for me and had my back, I feel blessed to have such a supportive family.*

*Nikki you are the best, you have been there and supported me through all the hardship and my never ending rants. Thankyou for being there, for understanding me and encouraging me to work harder.*

*Nasima you are more than a friend to me, thankyou for all the wonderful memories, the adventures and most importantly the emotional support. Kranti, we have a lot of wonderful memories in such a short time, I am glad to have you as my friend. Sabin, Dilli and Mridul you guys are amazing and wonderful friends, thankyou for all your support. Kristi, Swati, Urwee thankyou for all the good time we have had together. Our Nepali gang Prabuddha, Sasish, Biraj, Aashish, Sazna thankyou for your support.*

*Some of the wonderful people that have made my journey at AJJSH better, Anuj Dai, Bebek dai, Anup dai, Mayel di, Shreyas, Dipti, Merina, Aswathy I am grateful to you all.*

*My dissertation partners Jijinu and Ankit thankyou guys for the help.*

*Thankyou one and all who have helped me directly or indirectly.*

**Table of Contents**

---

<b>Chapter</b>	<b>Content</b>	<b>Page No.</b>
	List of figures	ii-v
<b>I</b>	Introduction	1-5
<b>II</b>	Methods	6-7
<b>III</b>	Maneuvers for the treatment of Posterior canal BPPV	8-21
<b>IV</b>	Maneuvers for the treatment of Lateral canal BPPV	22-44
<b>V</b>	Maneuvers for the treatment of Anterior canal BPPV	45-57
<b>VI</b>	Post-maneuver Restrictions	58-59
	Answers for MCQs	60
	References	61-73

---

**List of Figures**

<b>Figure No.</b>	<b>Title</b>	<b>Page No.</b>
<b>3.1</b>	Sign and symptoms of PC-BBPV as Characterised by Von Brevern et. al. (2015)	8
<b>3.2</b>	Figure showing the different head positions of the Epley maneuver	10
<b>3.3</b>	Figure showing different positions of the Semont Maneuver	12
<b>3.4</b>	Figure showing different positions of the Gans repositioning Maneuver	14
<b>3.5</b>	Figure showing different positions of the Bashir Maneuver	16
<b>3.6</b>	Figure showing different positions of the Half somersault exercise	18
<b>4.1</b>	Figure showing different positions of the Appiani maneuver for Geotropic HC-BPPV	24



---

<b>4.2</b>	Figure showing different positions of the Appiani maneuver for Apo-geotropic HC-BPPV	25
<b>4.3</b>	Figure showing different positions of the Vannucchi-Asprella maneuver	26
<b>4.4</b>	Figure showing different positions of the Barrel roll	28
<b>4.5</b>	Figure showing different positions of the Gufoni maneuver for Geotropic HC-BPPV	30
<b>4.6</b>	Figure showing different positions of the Gufoni maneuver for apogeotropic HC-BPPV	31
<b>4.7</b>	Figure showing different positions of the Kurtzer Hybrid Maneuver	33
<b>4.8</b>	Figure showing different positions of the Lempert log roll	34

---

---

<b>4.9</b>	Figure showing different positions of the Li's maneuver	36
<b>4.10</b>	Figure showing different positions of the Liberatory maneuver	37
<b>4.11</b>	Figure showing different positions of the Square wave maneuver	38
<b>4.12</b>	Figure showing different positions of the Forced Prolonged position	39
<b>4.13</b>	Figure showing different positions of the Zuma maneuver	41
<b>5.1</b>	Figure showing different positions of the Garaycochea Maneuver	47
<b>5.2</b>	Figure showing different positions of the Kim's Maneuver	48
<b>5.3</b>	Figure showing different positions of the Prolonged forced position procedure	49

---

---

<b>5.4</b>	Figure showing different positions of the Reversed CRP maneuver	51
<b>5.5</b>	Figure showing different positions of the Short CRP maneuver	52
<b>5.6</b>	Figure showing different positions of the Yacovino maneuver	54

---

## Chapter-I

### INTRODUCTION

Benign paroxysmal positional vertigo (BPPV) is characterized by short spells of vertigo triggered by the change in head position (Yang et al., 2019). As the name BPPV itself suggests, the symptoms occur after a certain position change and the vertigo is of sudden and rapid onset hence called paroxysmal (Von Brevern et al., 2015; Bhattacharyya et al., 2017). It is one of the common causes of vertigo and accounts for about 1/3 of all vestibular disorders (Agrawal et al., 2013). BPPV is the most prevalent (0.46%) condition among peripheral vestibular disorders (Hulse et al., 2019). It has also been reported that females are more susceptible to BPPV than males (Hulse et al., 2019). 8% of the individuals with severe or moderate vertigo are diagnosed with BPPV, making it a common cause of vertigo/ dizziness (Von Brevern et al., 2007). Bhattacharyya et al. (2017) reported that BPPV is a primary complaint in 17 to 42 % of subjects with dizziness.

Most of the time, BPPV has been found to occur in isolation with idiopathic causes. Idiopathic BPPV has its onset at around the fifth decade of life suggesting an age-related factor however; it can also be caused by conditions such as head trauma and vestibular neuritis (Baloh et al., 1987). Individuals with Meniere's disease are predisposed to BPPV (Gross et al., 2000). Idiopathic causes account for 73.83% of the cases with BPPV, head trauma in 8.72%, migraine for 8.72%, Meniere's disease in 4.65%, and other causes in 4% of the total cases reported of BPPV (Swain et al., 2018). Inner ear surgery such as stapedectomy has also been found to cause BPPV known as

Secondary BPPV that is caused due to the damage during the surgery to the utricle (Atacan et al., 2001).

The otoconia particles normally present in the macula of the utricle get dislodged and fall into one or multiple semicircular canals causing positional vertigo (Fife, 2009). Two theories have been proposed to explain the pathophysiology of the BPPV. The theories that have been proposed to explain the pathophysiology of BPPV are known as cupulolithiasis and canalithiasis. The presence of free-floating otoconia in the canals is called Canalithiasis (Hall et al., 1979), while on the contrary, if the otoconia are adherent to the cupula, it is known as Cupulolithiasis (Schuknecht, 1962). The inertia of the otoconia displaces the cupula following a particular head movement causing vertigo (Campbell et al., 2019).

The otoconia debris can enter any one of the three canals. As per the involvement of the different canals, these are known as, Posterior canal BPPV, Lateral canal BPPV, and Anterior canal BPPV, or it can also affect more than one semicircular canal at a time i.e. multi-canal BPPV (Fife, 2009). The posterior canal BPPV is the most common type of BPPV, accounting for 80%-90% of the total cases, followed by the lateral canal, which accounts for 5%-30%, and the rarest one is anterior canal BPPV that accounts for about 1 to 2% of the total BPPV cases (Von Brevern et al., 2015). Other rare types of BPPV are multi-canal BPPV & bilateral multi-canal BPPV (Bhattacharyya et al., 2017).

Individuals suffering from BPPV can have varying types and degrees of symptom depending on the canal affected and pathophysiology of the condition. Regardless of the canal, nystagmus and vertigo are evident in each individual with BPPV. The type and the duration of the symptoms may vary from one person to another. The nystagmus is

vertical type for the vertical canal BPPV and horizontal type in the case of the horizontal canal BPPV. The direction depends on the canal affected, and if the affected canal is the horizontal semicircular canal, the nystagmus can be direction changing. Similarly, the latency and the duration of the nystagmus can help in differentiating between cupulolithiasis or canalithiasis.

BPPV is not a life-threatening condition; however, it affects one's efficacy at work, it also intervenes with daily activities such as driving and going out of the house (Von Brevern et al., 2007). Due to episodes of vertigo resulting from BPPV, there is a negative impact, especially on working individuals with problems like reduction in workload, losing out on working days, quitting, or changing their jobs (Benecke et al., 2013). There is a reduction in the daily activities scores and depression in older adults (Oghalai et al., 2000).

Several options are available for the treatment of BPPV. Some patients with BPPV are treated with medications like vestibular suppressants, labyrinthine sedatives and antihistamines. The surgical line of treatment is very rarely opted and is done only in extreme circumstances (Fife, 2009; Sundararajan et al., 2011; Hilton & Pinder, 2014). Repositioning maneuvers are the main line of treatment for BPPV (Fife, 2009; Hilton & Pinder, 2014). These maneuvers consist of a sequential change in the position of the subject's head such that the otoconia debris moves back into the utricle. By performing the maneuvers one can eliminate the root pathology of the disease. The repositioning maneuvers have been proven to be more effective when compared to the medications like labyrinthine sedatives (Sundararajan et al., 2011).

Different maneuvers have been developed for the different types of BPPV. The Epley's maneuver and Semont liberatory maneuver are used to treat posterior canal BPPV (Parnes et al., 2003; Hilton & Pinder, 2014). In the case of lateral canal BPPV, Barbecue maneuver, Gufoni maneuver, and Vannucchi-Asprella maneuver are used (Libonati, 2005; Oron et al., 2015). The Yacovino maneuver and reversed Epley maneuvers are applied in cases with anterior canal BPPV (Yacovino et al., 2009; Anagnostou et al., 2015). The Epley maneuver and Semont maneuver are efficient with an efficacy rate of 93% and 77%, respectively, and safe for the treatment of posterior canal BPPV (Soto et al., 2001; Liu et al., 2016). Epley(1992) discovered the efficacy of his technique to be 80%. The Gufoni maneuver is effective on 83.8% of the subjects compared to a SHAM treatment with only 10% efficacy (Mandala et al., 2013). In a study where the Gufoni maneuver and barbecue roll were compared, it was found that both the methods are valid for the treatment of lateral canal BPPV with a success rate of 93% and 81% respectively (Casani et al., 2011). Steenerson et. al. (2005) carried out a study on 923 subjects with posterior or horizontal canal BPPV using canalith repositioning, log roll maneuvers and liberatory maneuvers as treatment and concluded the success rate to be 94%, 100%, and 98%, respectively. Another study has shown the efficacy of the deep head hanging maneuver for anterior canal BPPV to be 95%( Al Saif et al., 2012).

### ***1.1 Need for the study***

The success rate/ efficacy of the repositioning maneuvers are high for all three canal types of BPPV (Soto et al., 2001; Casani et al, 2011; Al Saif et al., 2012). Even though medications and surgical interventions are also available, they seem to be ineffective for the treatment of BPPV with a high rate of reoccurrence of the disorder (Semont et al.,

1988; Parnes et al., 2003). The sequential steps of the maneuvers put the subject in certain positions such that the otoconia debris eventually settles back into the utricle where it does not create any adverse effect. There are several repositioning maneuvers for each type of BPPV. The repositioning maneuvers have also been proven to be a more cost-effective treatment option with a minimum number of visits to the physician (Li et al., 2000; Bhattacharyya et al., 2017). These maneuvers have also been observed to improve the posture and quality of life in subjects suffering from BPPV(White et al., 2005). Unfortunately, there is a dearth of tutorials on BPPV repositioning maneuvers. Therefore there is a need to compile all the maneuvers for a more effortless way to get information on them such that it further helps the clinicians that deal with BPPV.

### ***1.2 Aim of the study***

To formulate a tutorial on the repositioning maneuvers for BPPV.

### ***1.3 Objectives of the study***

***The main objectives of the study are as follows:***

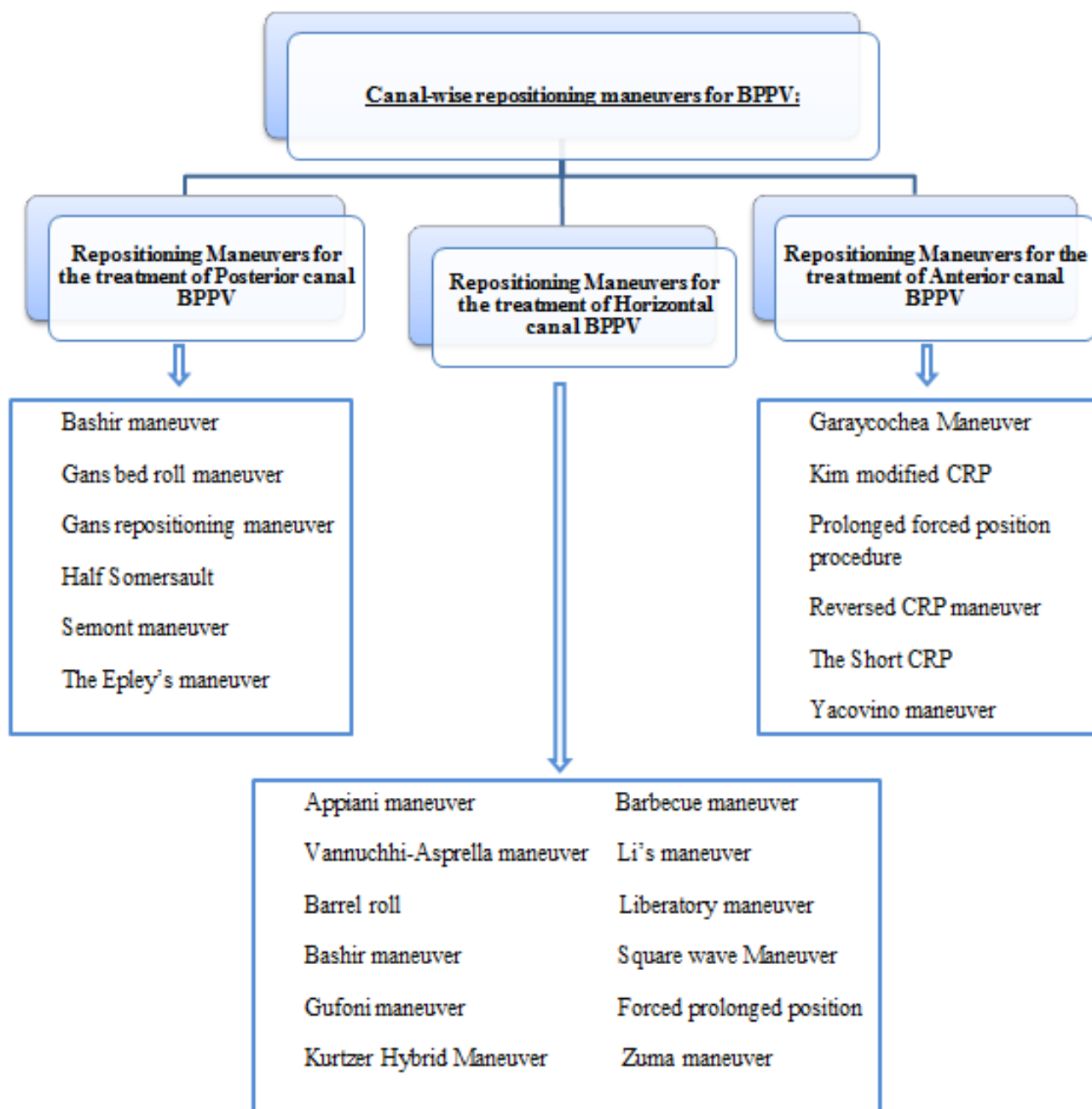
- ❖ To compile all the repositioning maneuvers available in the literature.
- ❖ To describe each of the repositioning maneuvers step by step in a sequential manner.
- ❖ To describe each of the repositioning maneuvers using appropriate pictures.



## Chapter-II

### METHODS

The data was collected via articles available in online sources as well as from textbooks. Original articles published by the authors of the maneuvers were collected along with the articles related to BPPV. The information on various repositioning maneuvers was searched in sources like Google Scholar, Google, Web of Science, Pubmed, Pubmed central, etc. Search words such as "repositioning maneuvers, BPPV treatment, lateral canal BPPV, Posterior canal BPPV, Anterior canal BPPV, etc." were entered into different databases in different combinations using Boolean operators such as AND, OR, NOT. Original articles on the maneuvers were compiled canal-wise as listed below.



Each maneuver was described with necessary details and illustrated using appropriate pictures for each of the sections/ chapters. A pre- post-assessment with minimum of 10 questions was included with each type of canal maneuvers that incorporated short questions and/ or multiple-choice questions along with the answer key at the end of the sections. Content validation was carried out for all of the questions.

## Chapter-III

### Maneuvers for the treatment of Posterior canal BPPV

The posterior canal BPPV is the most common type of BPPV out of the three canal types. Patients with BPPV of the posterior canal can have cupulolithiasis and canalithiasis. Specific symptoms of BPPV vary between cupulolithiasis and canalithiasis. Von Brevern et. al. (2015), characterized the sign and symptoms exhibited by patients with posterior canal BPPV for both cupulolithiasis and canalithiasis. The same is summarized in figure-3.1

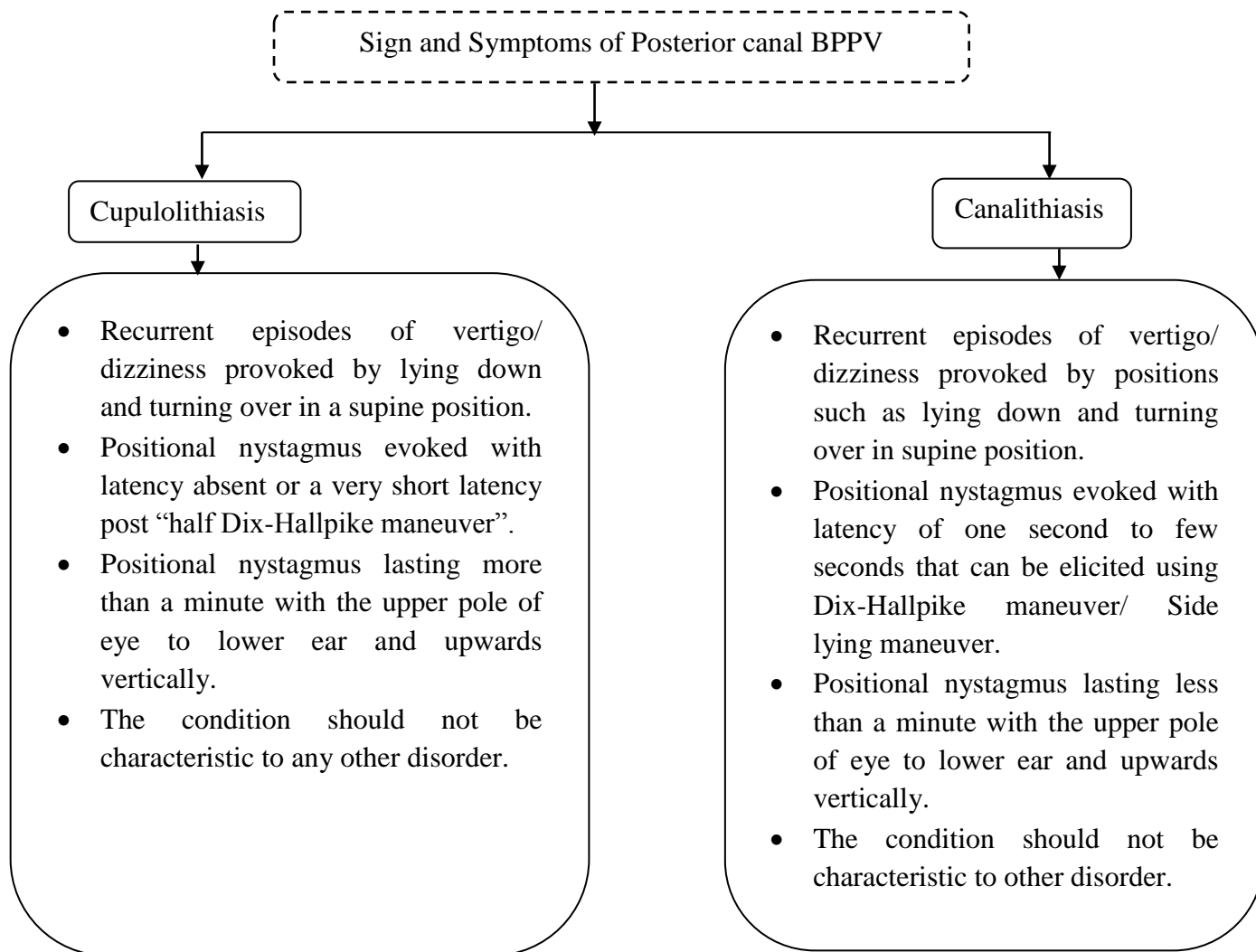


Figure 3.1. Sign and symptoms of PC-BBPV as Characterised by Von Brevern et. al. (2015)

To diagnose the posterior canal BPPV, tests such as the Dix-Hallpike maneuver and side-lying maneuver can be carried out (Cohen, 2004). Canalithiasis is more prevalent in the PC-BPPV compared to cupulolithiasis (Imai et al., 2009). 80-90% of all PC-BPPV patients have canalithiasis (Nakayama and Epley, 2005). The posterior canal BPPV can be treated by various maneuvers, the Epley's maneuver and Semont maneuver were the earliest maneuvers introduced and many more maneuvers have followed. The disappearance of the positional nystagmus and vertigo/ dizziness after the maneuvers indicate the elimination of otoconia from the semicircular canal.

### **3.1 Epley's Maneuver (Epley, 1992):**

The Epley's maneuver also known as **CRP** (canalith repositioning procedure) uses the positional changes as well as induced vibration to move the otoconia debris out of the semicircular canal and into the utricle. An oscillator can be used during the maneuver: a bone vibrator is placed on the ipsilateral ear's mastoid, which prevents the otoconia debris from adhering to the structures during the positional changes. This maneuver is carried out in the following steps:

- The subject is seated on the patient's bed facing front.
- The head of the subject is rotated 45-degrees to the affected side and then brought to a supine position with the head hanging below the table, bringing the otoconia debris to the center of the canal.
- The subject remains in this position for thirty seconds or till the symptoms cease.
- Once the symptoms have subsided, the head is rotated 45 degrees from the center to the opposite side, which is the unaffected side that is a total rotation of 90 degrees from the previous head position. This causes the debris to move towards

the common crus. The subject remains in this position for thirty seconds or till the symptoms subside. In the next step, the head and the body of the subject are rotated such that it is facing 135 degrees downwards from the previous position causing the debris to cross over the common crus. In this position basically, the patient is sleeping on the unaffected side shoulder with the head hanging down.

- Lastly, with the head turned to the unaffected side, the subject is seated up then the head is turned forward and the chin is lowered by 20 degrees, resulting in the otoconia debris entering into the utricle.

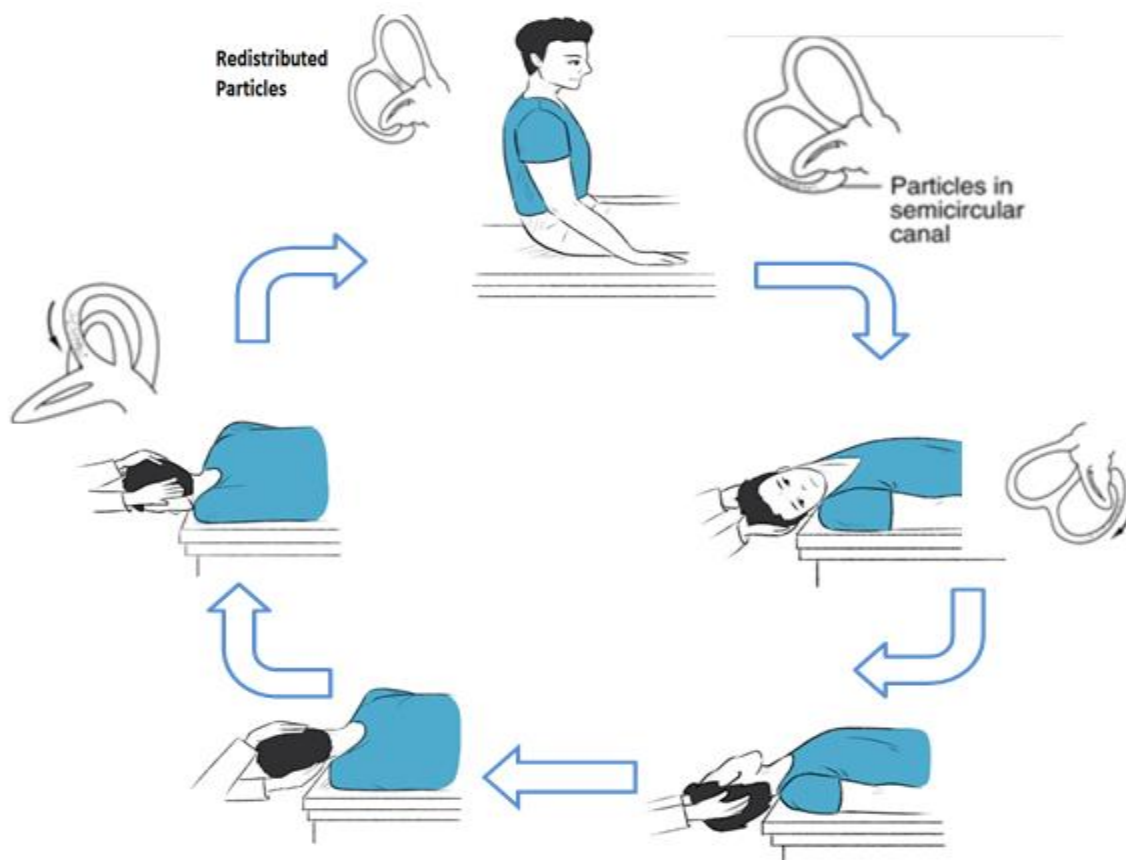


Figure-3.2. Figure showing the different head positions of the Epley maneuver

Otoconia debris within the semicircular canal moves with every change in head position, causing nystagmus, vertigo, and/ or vomiting. During the maneuver, as the

otoconia settle down in the semicircular canal in a particular head position, the intensity of the nystagmus and vertigo reduces. Subject should be held in each head position for a minimum of 30 seconds or till the sign and symptoms such as vertigo and nystagmus disappear. So the clinician should wait until vertigo/ nystagmus ceases before moving to the next position.

During the Epley maneuver, the patient perceives that they are falling backward within one minute of resuming the sitting position. This phenomenon resembles a Tumarkin crisis triggered by the redistribution of repositioned otoconial debris in the utricle macula (Maranhão et al., 2018). Tumarkin crisis is also considered as an indicator of successful therapeutic results (Maranhão et al., 2018).

The efficacy of the Epley's maneuver is indicated by a negative Dix-Hallpike test post maneuver. It is shown to resolve the condition timely and is cost-effective. However, a frequent difficulty of this maneuver is cervical pain (Sabeti et al., 2017). Sakata et. al. (2004) stated not using the Epley maneuver in older subjects due to high cervical issues.

### **3.2 Semont's Liberatory maneuver (Semont et al., 1988):**

Semont proposed a maneuver that uses the inertia of the otoconia debris and endolymph's pressure to move the debris out of the PSCC. The maneuver is carried out in the following steps:

- The subject is seated in the middle of the examination table with both legs down.
- The subject's head is rotated 45° away from the affected side. Maintaining this head position, the patient is rapidly laid back onto a side-lying position toward the affected side on the examination table in the next stage. This causes the cupula to be in line with the plane of gravity thereby, the movement of the cupula due to

presence of the otoconia in the semicircular canal causes nystagmus that is torsional and beating to the affected side. The position should be maintained till the nystagmus disappears plus 2-3 minutes.

- Next, the subject is rapidly moved to the opposite side-lying position, maintaining the original head alignment of the head rotated away from the affected side. In this second position, nystagmus will be seen but of a lesser frequency and a wider amplitude.
- If nystagmus is not seen in the second step, then the head is slowly turned nearly to 90° facing up and then quickly turned to 45° facing down. The subject must stay in this last position for at least 5 minutes and is brought back to upright position very slowly.

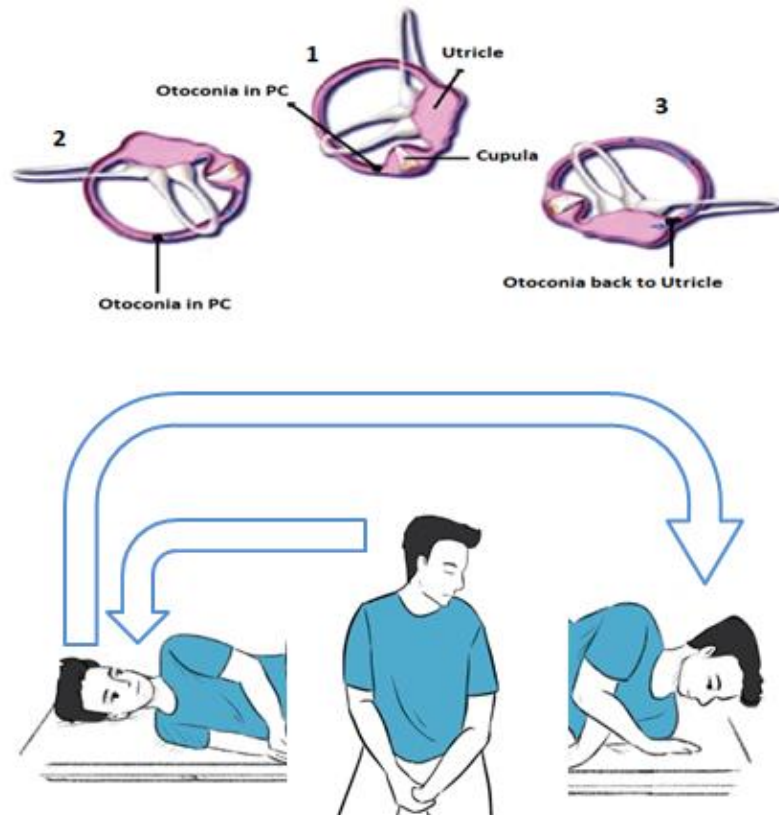


Figure 3.3: Figure showing different positions of the Semont Maneuver

With every change in position, there is a movement of otoconia debris within the semicircular canal that can cause nystagmus, vertigo, and/ or vomiting. The clinician should wait until vertigo/ nystagmus ceases before moving to the next position. One of the important aspects of the Semont maneuver is the speed of the 180-degree movement from one side to another, this 180-degree swing should be done within a time of 1.5 seconds (Faldon & Bronstein, 2008). If the change in position is not rapid and is slow, the otoconia debris will not move out of the canal efficiently.

After the maneuver, the subject is then asked to keep his head absolutely vertical in space for at least 48 hours during day and night. He/ she is asked to avoid fast head movements upward or downward and not to sleep on the vertigo-generating side for a week. If the maneuver is not successful, it is performed again a week later. One of the modifications in the Semont maneuver was the reduction in the time between the change in the position, that is holding the position for 10 seconds after cessation of nystagmus rather than 2-3 minutes (Cohen & Jerabek, 1999). Sakata et. al. (2004) stated to not use the Semont maneuver in older subjects due to high chances of cervical issues. Also, subjects with any mobility issues including the back or hip are contradicted from using this maneuver due to the risk associated with sudden movements (Roberts et al., 2006).

### **3.3 Gans repositioning maneuver (Roberts et al., 2006):**

The gans repositioning maneuver (GRM) is a hybrid approach and compromises steps of canalith repositioning maneuver and Semont's liberatory maneuver. It was developed to be used in subjects with mobility issues, cervical issues, and back problems. This maneuver is carried out following the given steps:



- The GRM starts with the subject seated facing forward with legs hanging below the patient's bed.
- The head is turned 45° to the unaffected side, and then he/she is put in a side-lying position towards the opposite that is the affected side (in this position, the otoconia debris comes to the center of the canal).
- The subject is rolled from the affected side to lie sideways to the unaffected side, with head at 45° to the same that is the unaffected side (in this position, the debris comes to the common crus). A liberatory headshake is done which results in the otoconia debris moving from the common crus.
- Finally, the subject is seated with the head facing front (the debris exits the canal and enters into the utricle).

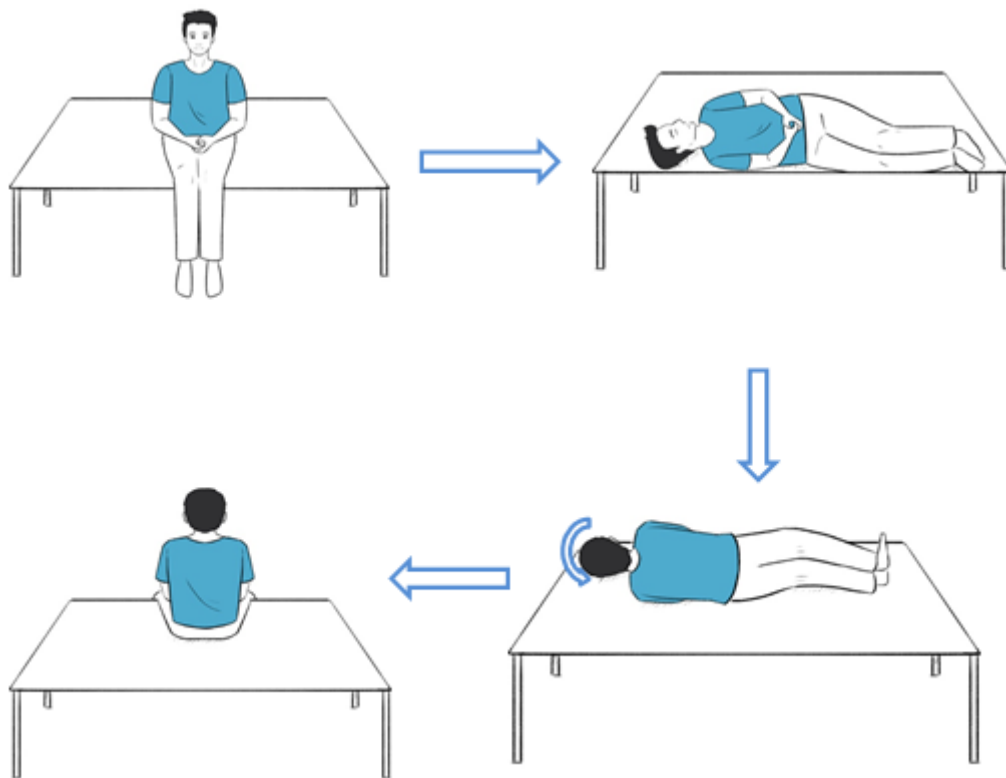


Fig 3.4: Figure showing different positions of the Gans repositioning Maneuver

The patient should be held in each of the positions for 60 seconds or until vertigo ceases. With every change in head position, there will be movement of the otoconia debris within the semicircular canal that can cause nystagmus, vertigo, and/ or vomiting. So the clinician should wait until vertigo ceases before moving to the next position. Additionally, a towel or a sheet is used for an effortless and smoother transition of the steps and is called **Gans repositioning maneuver with bedroll**. Subjects are free from the condition when no nystagmus and vertigo are elicited after a diagnostic positional maneuver. Gans maneuver causes fewer complications and is more appropriate for subjects with cervical issues and older adults (Saber et al., 2017).

#### 3.4 **Bashir Maneuver** (Bashir et al., 2016):

The Bashir maneuver was introduced as a single maneuver for the treatment of all three canal types of BPPV. It comprises steps from the deep hanging maneuver, Epley maneuver, and Lambert maneuver. Following are the steps of the Bashir maneuver:

- This maneuver is performed on a mat. First, the subject has to lay sideways towards his/her affected side and the head is turned towards the floor. This step results in the movement of the otoconia debris towards the center of the semicircular canal.
- In the next step, the subject is made to sleep in the supine position.
- Next, the subject is turned towards their unaffected side and the head is facing the floor causing the debris to further move towards the common crus.
- Lastly, the subject has to sit up with their chin touching the chest thereby bringing the debris out of the canal and into the utricle.

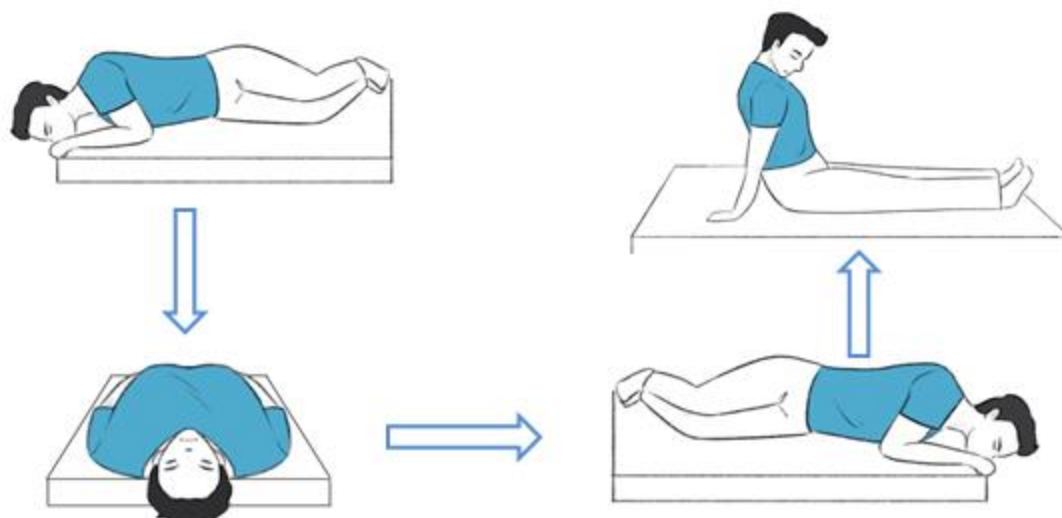


Fig 3.5: Figure showing different positions of the Bashir Maneuver

Each position has to be maintained for 30-60 seconds. With every change in position, there is movement of the otoconia debris within the semicircular canal that can cause nystagmus, vertigo, and/ or vomiting. So the clinician should wait until vertigo/ nystagmus ceases before moving to the next position. After the maneuver, if no symptoms like vertigo/ nystagmus are seen then it is full recovery. This maneuver is appropriate for subjects with arthritis of the hips and spine and also subjects with obesity as the maneuver is not very demanding physically.

### 3.5 Half Somersault Exercise (Foster et al., 2012):

Half somersault maneuver was developed as a self-administering exercise to be done at home that does not require the help of a clinician. The subject can perform the maneuver on the floor or at the center of a bed.

- First, the subject has to kneel down, the head is then quickly tipped up and back resulting in movement of the otoconia debris towards the center.

- Next, the patient is asked to place the head on the floor upside down as if the patient is about to somersault. Tuck the chin of the patient in this position in a way such that the patient's head touches the floor near the back of the head rather than near the forehead. This position may cause a burst of vertigo. Without moving, ask the patient to wait until any vertigo ends. Vertigo means the particles are moving in the proper direction.
- Ask the patient to Slowly turn their head by 45-degrees towards the affected side elbow. Try to center the right elbow in your field of view. Instruct the patient that his/her head will be kept in the same position for the rest of the maneuver. Again, wait for any vertigo to end before moving to the next step.
- Keeping the head turned to the right and viewing their affected side elbow, ask the patient to QUICKLY raise their head to the shoulder level. The patient's head should be positioned at about 45 degrees angle to the floor throughout this move. Vertigo is normal during this part of the procedure. Wait for vertigo to end or count to 15 before continuing.
- Ask the patient to raise their head to the upright position QUICKLY, keeping it about halfway turned toward the affected shoulder. Some additional vertigo may occur. After vertigo subsides, make the patient slowly sit upright. Let the patient rest for 15 minutes.
- After the rest, quickly tip the patient's head up and down. If no dizziness occurs, do not repeat the maneuver. If the patient still feels some dizziness when making that movement, repeat the maneuver. You may also repeat the maneuver if the patient has another vertigo spell in the future.

- As the half somersault position has to be assumed by subjects, it is not advised for individuals with obesity, neck injury, back injury, or impaired flexibility.

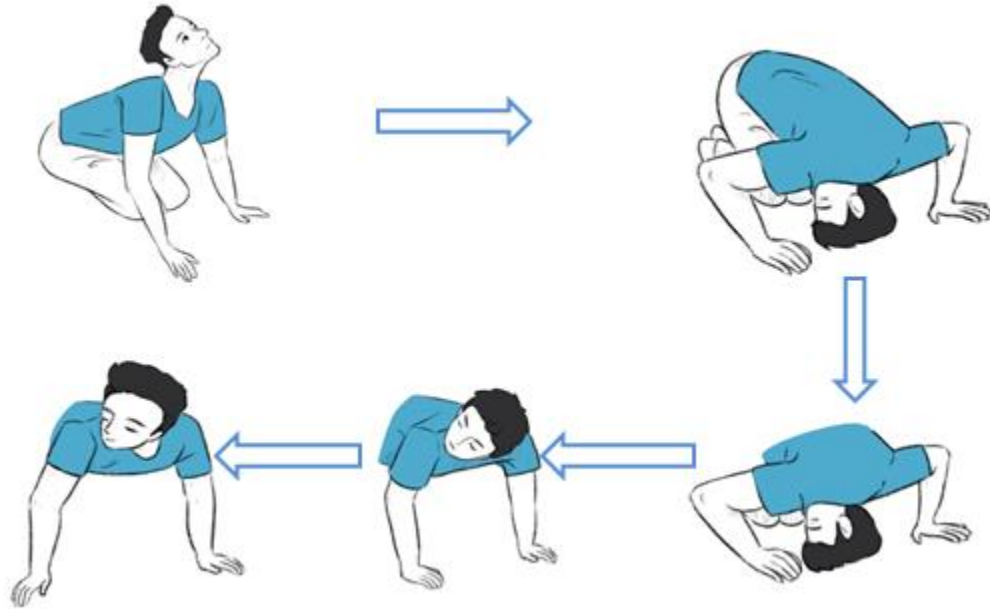


Fig 3.5: Figure showing different positions of the Half somersault exercise

**QUESTIONS FOR PC-BPPV REPOSITIONING MANEUVERS**

1. In the Epley's maneuver, the subject is initially.....
  - a. Brought to a supine position.
  - b. Head turned to unaffected side and brought to supine position.
  - c. Head turned to affected side and brought to supine position.
  - d. Brought to a prone position.
2. For the Semont maneuver to be efficient, the 180 degrees swing must be done.....
  - a. Within 2 seconds
  - b. Between 1-2 seconds
  - c. Within 1.5 seconds
  - d. Less than 0.5 seconds
3. The Gans repositioning maneuver(GRM) comprises steps of which two maneuvers?
  - a. Epley's Maneuver & Semont's liberatory maneuver.
  - b. Epley's Maneuver & Half Somersault maneuver.
  - c. Half Somersault & Semont's liberatory maneuver.
  - d. Epley's Maneuver & Bashir maneuver.
4. In which position does the otoconia debris come to the common crus in CRP and GRM?
  - a. When the head is rotated 45 degrees to the affected side.
  - b. When the head is rotated 45 degrees to the opposite side that is the unaffected side.

- c. When the subject lies in supine position.
  - d. When the subject is rotated to the side.
5. How the Gans Bed roll Maneuver is different from GRM?
- a. A towel or a sheet is used for an effortless and smoother transition of the steps in Gans bed roll maneuver.
  - b. The subject is asked to roll over the bed himself.
  - c. A bed-sheet is used to roll it over the subject thereby restricting his/her movement.
  - d. Additional prone position has to be performed.
6. What is the first position in half somersault maneuver?
- a. Sitting facing front
  - b. Supine position with head turned to unaffected side.
  - c. Kneeling down.
  - d. Prone position.
7. How long should a position be sustained for?
- a. It should be sustained for 15 seconds irrespective of the nystagmus.
  - b. It should be sustained till the symptoms i.e. nystagmus subsides plus 15-30 seconds after that, if no nystagmus for 15-30 seconds. (Depends on each maneuver)
  - c. Position should be changed as soon as the nystagmus vanished.
  - d. Position should be changed as soon as nystagmus is seen.

8. Name a maneuver that was designed as a single maneuver to treat all three canal BPPV:
- a. Epley's Maneuver
  - b. Gans repositioning maneuver
  - c. Semont Liberatory Maneuver
  - d. Bashir maneuver
9. Which maneuver can be used in subjects with mobility issues, cervical issues and back problems?
- a. Epley's Maneuver
  - b. Gans repositioning maneuver
  - c. Semont Liberatory Maneuver
  - d. Half Somersault maneuver
10. Name the maneuver that was developed as a home exercise and can be done without the help from clinician:
- a. Epley's Maneuver
  - b. Gans repositioning maneuver
  - c. Semont Liberatory Maneuver
  - d. Half Somersault maneuver
11. In the first step of Semont's maneuver .....
- a. The subject's head is rotated  $45^\circ$  away from the affected side onto a side lying position.
  - b. The subject is rapidly laid back onto a side- lying position.
  - c. The subject's head is rotated  $45^\circ$  away from the unaffected side.
  - d. The subject is elevated  $30^\circ$  in supine position.
12. .... indicates the resolution of the PC-BPPV
- a. Reduction in the severity of symptoms post provoking positions.
  - b. Absence of symptoms post provoking positions.
  - c. Change in the type of nystagmus.
  - d. Increased velocity of nystagmus.



## Chapter-IV

### Maneuvers for the treatment of Lateral canal BPPV

The lateral canal BPPV is the second most common type after the posterior canal type accounting for about 5-30% of the total BPPV cases (Von Brevern et al., 2015). The pathophysiology behind this condition can be canalithiasis or cupulolithiasis wherein canalithiasis is seen to be the ruling cause. The nystagmus seen in HC- BPPV is of a purely horizontal type. Based on the nystagmus the HC-BPPV can be differentiated as geotropic or apogeotropic. In the geotropic variant, the nystagmus beats toward the ground that is towards the ear that is down whereas in apogeotropic variant it beats away from the ground that is towards the ear that is up when placed in the supine position (Oron et al., 2015). The supine roll test is performed to diagnose HC-BPPV. The following features are evident in case of canalithiasis of HC-BPPV (Von Brevern et al., 2015):

- Reoccurring episodes of vertigo/ dizziness provoked by positions such as lying down and turning over in supine position.
- Positional nystagmus geotropic type induced while performing supine roll test.
- Geotropic direction changing nystagmus with absent or short latency.
- The attack lasts less than a minute.
- The condition should not be characteristic to other disorder.

The features of the subjects with cupulolithiasis of HC-BPPV are as follows (Von Brevern et al., 2015):

- Reoccurring episodes of vertigo/ dizziness provoked by positions such as lying down and turning over in supine position.

- Positional nystagmus apogeotropic type induced while performing supine roll test.
- Apogeotropic direction changing nystagmus with absent or short latency.
- The attack lasts more than a minute.
- The condition should not be characteristic to other disorder.

#### **4.1 Appiani maneuver** (Appiani et al., 2001; Appiani et al., 2005):

The appiani maneuver was first developed for the geotropic variety of LC-BPPV and later a modified version was introduced for the apo-geotropic type. In the geotropic type, following steps are carried out:

- The subject is first seated on the treatment bed facing forward with both legs hanging below.
- In the next step, the subject is brought into a side lying position on the unaffected side which brings the otoconia particles to the non-ampulated end, and this position is maintained till the nystagmus ceases plus one minute after that.
- Maintaining the side lying position, the subject's head is turned by 45 degrees downward towards the ground. The subject is kept in this position for 2 minutes. In this head position, the otoconia debris move out of the canal and enter into the utricle.
- Lastly, the subject is brought to the original seated position.

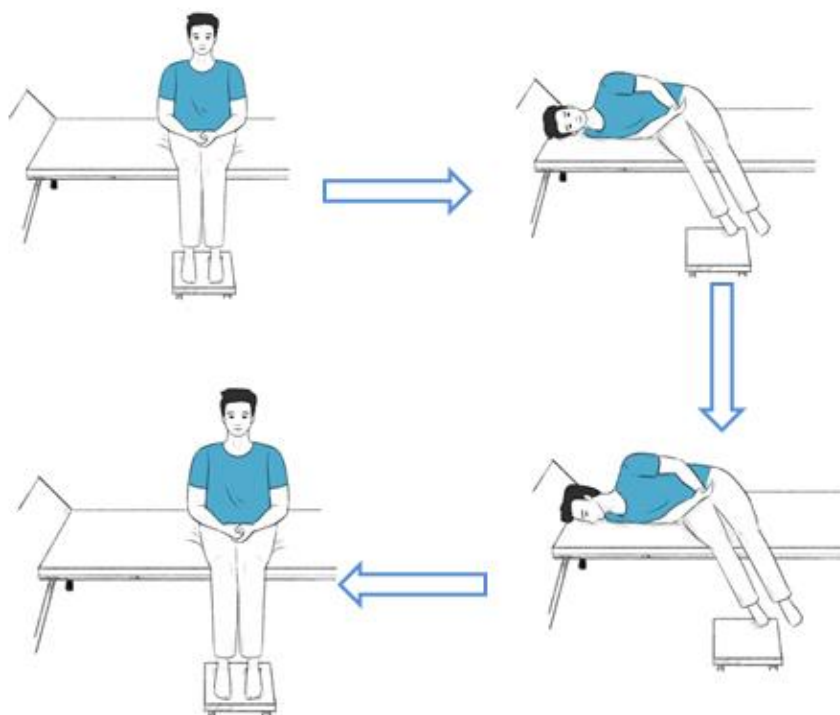


Figure 4.1 Figure showing different positions of the Appiani maneuver for Geotropic  
HC-BPPV

#### 4.1.1 Appiani maneuver for apo-geotropic type nystagmus

- The subject is first seated on the treatment bed facing forward with both legs hanging below the bed.
- The subject is brought into a side-lying position on the affected side which brings the otoconia particles towards the bottom side of the canal.
- Maintaining the side-lying position, the subject's head is turned 45 degrees upward. This causes the otoconia debris to move to the posterior arm of the lateral canal. The subject stays in this position for 2 minutes.
- Lastly, the subject is brought to the original seated position. This creates a shift from the apo-geotropic to the geotropic type and another maneuver to treat the geotropic type can later be applied to eradicate the condition completely.

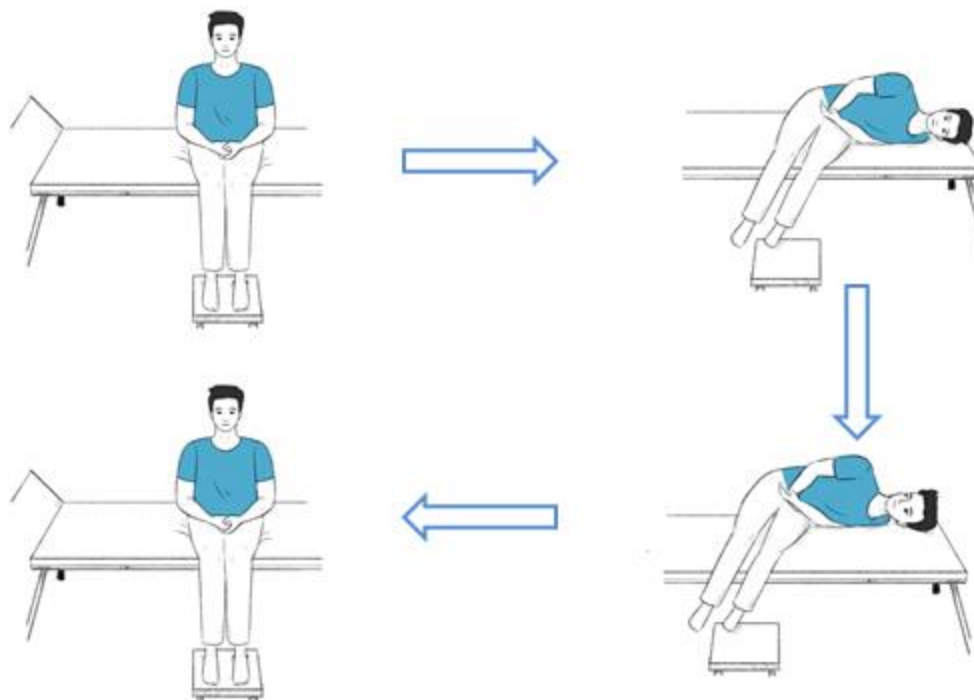


Figure 4.2 Figure showing different positions of the Appiani maneuver for Apogeotropic HC-BPPV

This maneuver is easier to perform on older adults and obese adults in comparison to the maneuvers that require rotation of the whole body, and it is also found to be more time-efficient.

#### **4.2 Vannucchi-Asprella maneuver** (Vannucchi & Giannoni, 1998):

This maneuver is used for both apogeotropic and geotropic types of LC-BPPV. Following steps are carried out in this maneuver:

- Initially, the subject has to lie in a supine position on the treatment bed.
- The head is quickly rotated towards the healthy side by 90°.
- Retaining the same head position, the subject is brought to a seated position, and then the head is also turned slowly to the center.

- Lastly, the subject is brought back to the supine position which determines success of the maneuver. If the nystagmus/ vertigo is absent after bringing the subject to the supine position it implies the successful eradication of debris from the horizontal canal however if the nystagmus/ vertigo still persists then the maneuver has to be repeated as it is an indication of presence of the otoconia debris within the horizontal canal.
- In case of persistence of the symptoms, the maneuver can be repeated five times or more until all the symptoms disappear (Libonati, 2005; Vannucchi et al., 2005)

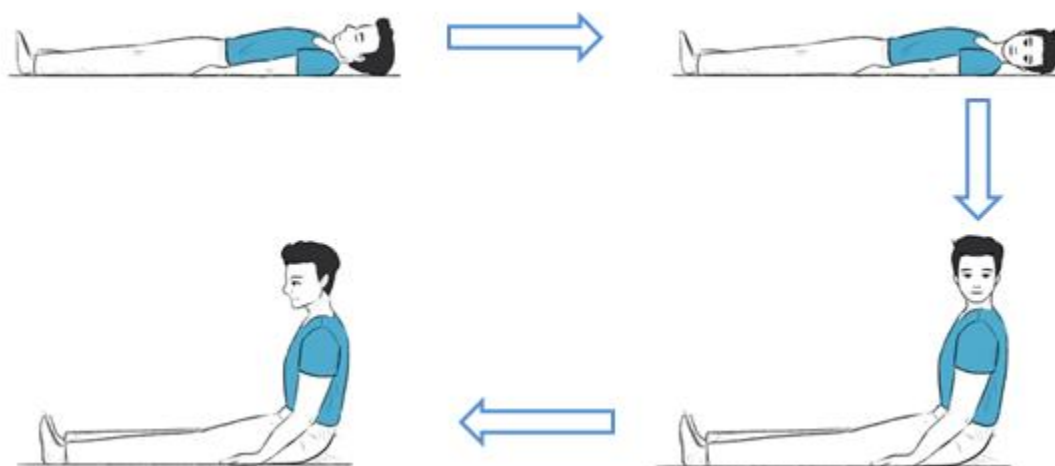


Fig 4.3: Figure showing different positions of the Vannucchi-Asprella maneuver

When the head is turned towards one side, the LSSC turns to the same side however due to the brisk movements used, the otoconia debris moves to the other side that is counterclockwise due to inertia henceforth it moves out of the SSC. The Vannucchi-Asprella maneuver can be used in both geotropic and apogeotropic variants of HC-BPPV. However, as the debris is closer to the cupula in case of cupulolithiasis, it may require multiple repetition of the maneuver to effectively free the canal of the debris

compared to canalithiasis. (Vannucchi et al., 2005). The position changes in this maneuver are easier than the maneuvers that require the complete rotation of the body therefore they are more convenient for subjects with mobility issues and restrictions..

#### **4.3 Barrel Roll (Epley, 2001):**

The Barrel roll is carried out for subjects with canalithiasis of the LC-BPPV. It is conducted using the following steps:

- The subject is placed in the supine position with the head turned towards the affected side.
- In the next step, the head is turned to the center in the supine position.
- In the supine position the head is turned to the opposite side, i.e unaffected side.
- The subject is turned to the prone position from the unaffected side, with the head facing down and center.
- Next, the subject is brought to a supine position with the head turned on the affected side thereby completing a 360° turn.
- Lastly, the subject is brought to a sitting position and the head is brought to the center.

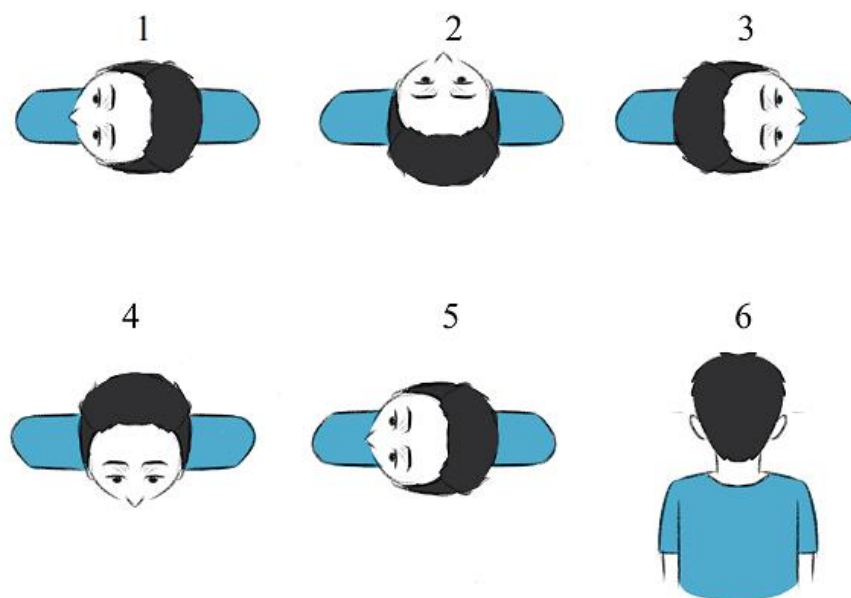


Fig 4.4: Figure showing different positions of the Barrel roll

Nystagmus/ vertigo/ vomiting can occur with the change in positions. If they are elicited after a positional change it indicates the movement of the otoconia debris, when the otoconia reach the end of the canal the nystagmus slows down and eventually stops this is when the position should be changed. Therefore, the clinician should wait for the nystagmus/ vertigo to cease plus an additional 30 seconds to move on to the next position. In subjects with mobility issues and obesity, turning the head  $135^{\circ}$  from supine position to the opposite ear is suggested and if symptoms persist, use of a positioning apparatus is recommended which straps the patient in a custom-built chair that rotates 360 degrees (Epley, 1997). However, this maneuver should be avoided with patients with obesity.

#### 4.4 Gufoni Maneuver (Gufoni et al., 1998):

The Gufoni maneuver can be administered in both geotropic and apogeotropic types of HC-BPPV. **Gufoni maneuver for Geotropic nystagmus** is carried out with the following steps:

- This maneuver starts in a front-facing sitting position with both legs down.
- The subject is tilted briskly to a side-lying position that is on the unaffected side. The subject maintains this position for 120 seconds.
- The head is turned down by 45° towards the ground and is maintained for 120 seconds.
- Lastly, the subject is returned to the initial sitting position by maintaining the same head position.
- For ease of learning, one can remember the Gufoni maneuver for geotropic nystagmus as G3. First G corresponds to Geotropic, the second G corresponds to Good ear, and the third G corresponds to the ground. So in simple words, if you have a patient with lateral canal BPPV and has a Geotropic type of nystagmus, move the person towards the good ear and then turn the head towards the ground.



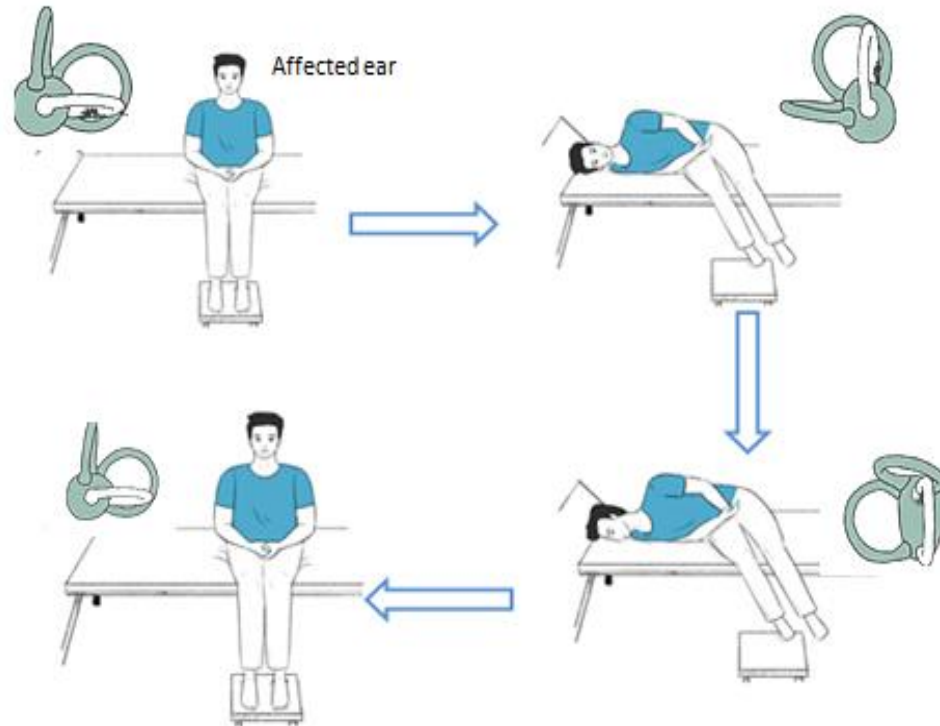


Fig 4.5: Figure showing different positions of the Gufoni maneuver for Geotropic HC-BPPV

#### **Gufoni Manuever for Apogeotropic nystagmus:**

- This maneuver starts in a front-facing sitting position with both legs down.
- The subject is tilted briskly to a side-lying position that is on the affected side. The subject maintains this position for 120 seconds.
- The head is turned 45° away from the ground, and this position is maintained for 120 seconds.
- Lastly, the subject is returned to the initial sitting position by maintaining the same head position.
- For ease of learning, one can remember the Gufoni maneuver for apogeotropic nystagmus as A3. First A corresponds to apogeotropic nystagmus, second A

corresponds to affected ear, and the third A corresponds to away from the ground. So in simple words, if you have a patient with lateral canal BPPV and has the apogeotropic type of nystagmus, move the person towards the affected ear and then turn the head away from the ground.

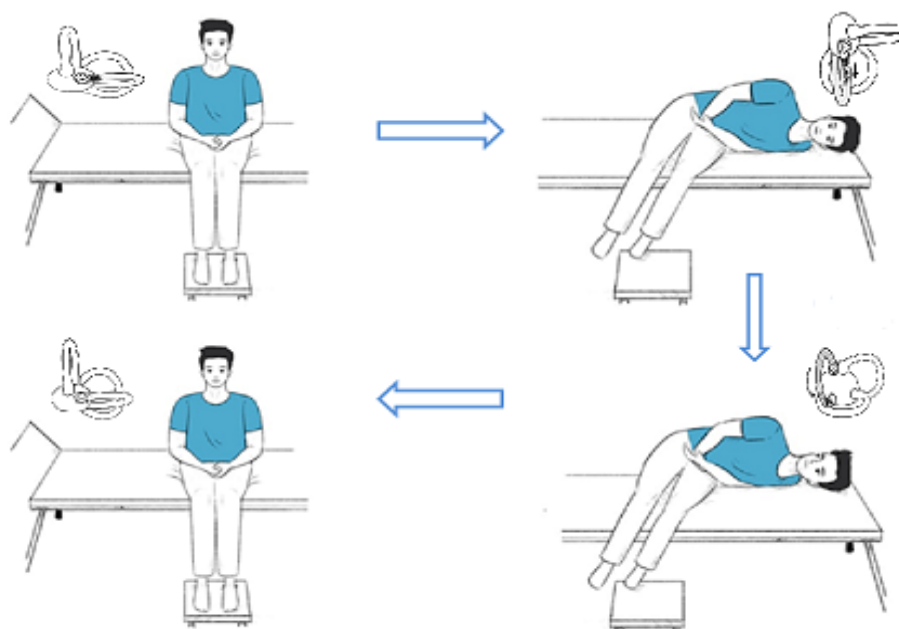


Fig 4.6: Figure showing different positions of the Gufoni maneuver for apogeotropic HC-BPPV

With every change in position, there is a movement of otoconia debris within the semicircular canal that can cause nystagmus, vertigo, and/ or vomiting. So the clinician should wait until vertigo/ nystagmus ceases before moving to the next position. The Gufoni maneuver is easier to perform than the other maneuvers that require rotation of the whole body especially in subjects with cervical diseases, obese or older subjects (Oron et al. , 2015). In some subjects, a conversion of the HC-BPPV to PC-BPPV was reported after this maneuver rather than a complete resolution (Testa et al., 2012). Hence a variation of the maneuver was introduced by Tesla et al (2012) where the second side-

lying step is divided into two steps: first a fast movement of 45° followed by a slower completion of step after 15 seconds that prevents the conversion to PC-BPPV.

#### **4.5 Kurtzer Hybrid Maneuver** (Gans et al., 2017):

This maneuver is a combination of the Gufoni, Appiani, and Casani maneuvers such that it can be used for all the variants of LC-BPPV. It is carried out with the following steps:

- In the first step, the patient begins in a position similar to a side-lying Hallpike test. With the patient's head rotated to the left, the patient has to lay on the right side. Usually, for lying down, the weaker side is preferred first as the patient may experience lesser symptoms when lying on the weaker side. However the patient may lie on any side first.
- In the next step, the patient has to lay on the right side with 30 degrees of neck flexion.
- In the next step, the patient's head is rotated nose-down with 30 degrees of flexion.
- Next, the patient has to turn the nose back up with 30 degrees of neck flexion and has to rotate the lower torso to the other side.
- The patient has to rotate the head nose-down with 30 degrees of flexion on the other side. This is the end of the Kurtzer Hybrid Maneuver.
- Precautionary, one additional step is done with the subject in the same side-lying position with the head aligned straight to the body and to look forward that is no neck rotation. Here, both nystagmus and vertigo must be absent.

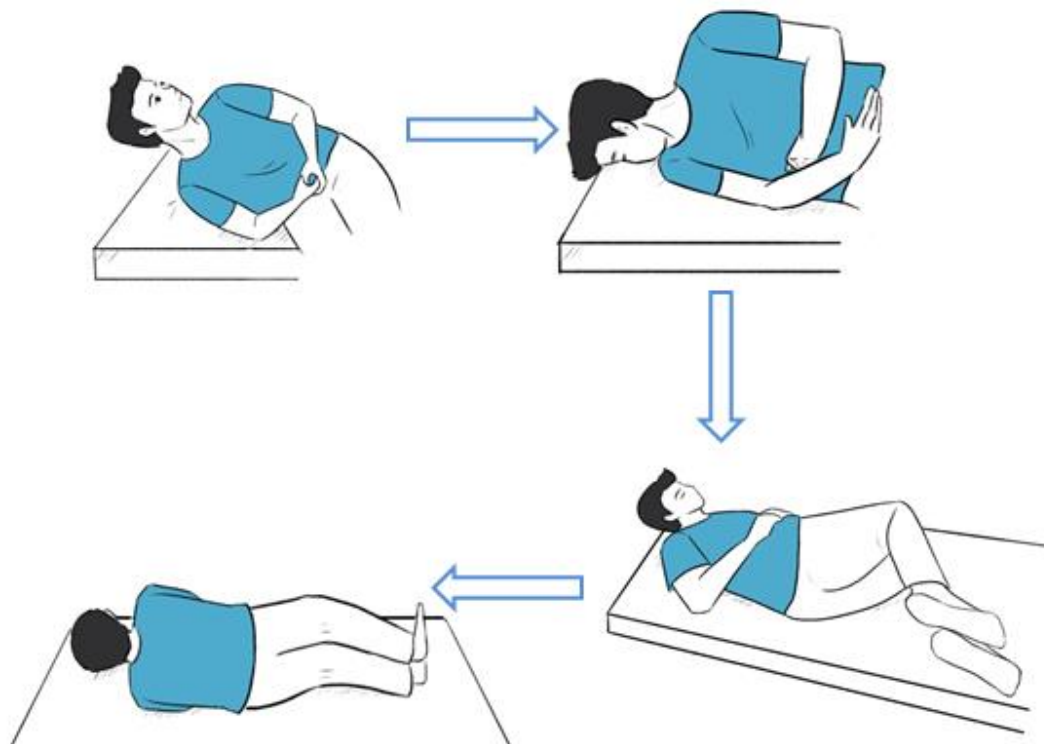


Fig 4.7: Figure showing different positions of the Kurtzer Hybrid Maneuver

With every change in position, there is a movement of otoconia debris within the semicircular canal that can cause nystagmus, vertigo and/ or vomiting. So the clinician should wait until vertigo/ nystagmus ceases before moving to the next position. The position should be maintained till the nystagmus/ vertigo ceases plus 60 seconds. This maneuver has only 4 steps and less changes in body position; hence it is a good option for subjects with orthopedic and mobility issues. Also, it is not compulsory in this maneuver to know the affected side. It has a lesser occurrence of emesis compared to other maneuvers.

#### **4.6 Lempert Log roll/ Barbecue roll (Lempert & Tiel-Wilck, 1996):**

Lempert and Tiel-Wilck (1996) introduced a maneuver for the HC-BPPV adapted from Epley's maneuver for PC-BPPV and can be used for canalithiasis of the HC-BPPV.

This maneuver comprises rotation of the subject's head by 270 degrees around his/ her longitudinal axis in steps of 90 degrees. Following steps are carried out for this maneuver:

- The maneuver starts with the subject in a supine position.
- The head is rotated to the unaffected ear in the next step.
- Next, maintaining the same head position, the body is turned from supine to a prone position.
- This position is followed by a head turn to a nose-down position.
- Next, the head is turned toward the opposite side that is the affected ear down position.
- Lastly, the subject is brought to a sitting position.

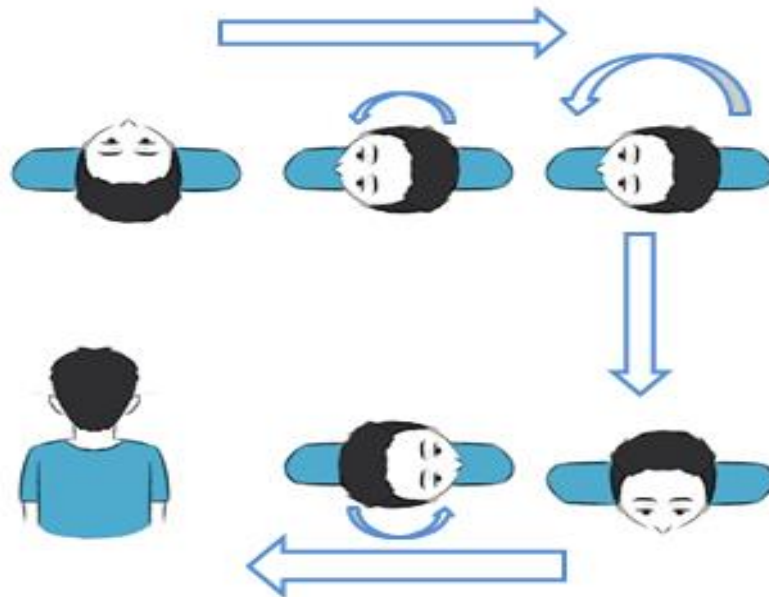


Fig 4.8: Figure showing different positions of the Lempert log roll

Each of the head rotations should be carried out within 0.5 seconds. The head position should be maintained for 30-60 seconds till the nystagmus subsides. The rapid 270-degree head movement induces the otoconia debris to move out from the canal and into the utricle. Baloh (1994) suggested an extra step of turning the head nose up, thereby making it a complete 360-degree rotation around the axis. Each head position should be maintained for a minute.

#### **4.7 Li's Maneuver (Li et al., 2015):**

Li's maneuver was developed as a quick maneuver that is easy to perform and less time-consuming. It can be used in the canalithiasis of HC-BPPV. This maneuver has only two steps:

- The subject is placed on a wide bed which has enough space for the subject to roll to the other side. The patient is placed sideways to the affected side that is if it is the right side HC-BPPV, the subject is placed on the right side of the wide bed. The clinician has to stand behind the subject holding their right hand using his/her right hand. The subject has to keep their feet together and stretch them straight keeping the legs parallel with the floor.
- Secondly, the subject is quickly rolled to the opposite that is the unaffected side to the other side of the bed. This position has to be maintained for 4 minutes.

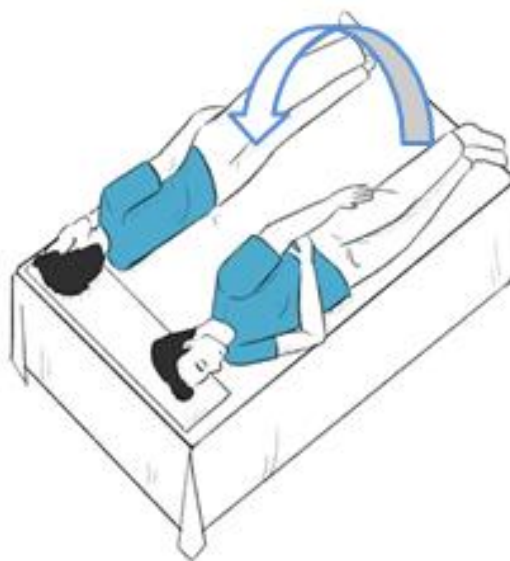

Fig 4.9: Figure showing different positions of the Li's maneuver

A higher success rate was associated with turns that were faster. The maneuver can be used for individuals with HC-BPPV who have a short neck, cervical spondylosis, or obesity as only one position change is there and it is less time-consuming.

#### **4.8 Liberatory maneuver** (De la Meilleure et al., 1996):

The liberatory maneuver can be used in the canalithiasis of the HC-BPPV. The pathological side has to be determined before carrying out the maneuver. It can be carried out in the following steps:

- The maneuver starts with the subject lying down in the supine position.
- In the next step, the head of the patient is ventroflexed by 30 degrees above from the bed/ table to bring the lateral canal in a more influential plane.
- The head of the subject is turned to the affected side in the next step. When the head is turned to the affected side, the debris i.e the otoconia move towards the ampulla that is geotropic nystagmus. As the head is turned to the pathological side

the nystagmus seen is intense. The head is kept in this position for at least five minutes.

- In the next step, the head is rapidly turned towards the other side by over 180 degrees with the head ventroflexed by 30 degrees which also causes nystagmus but is less intense as it is the unaffected side. In this step, the debris moves to the unampullated arm and out of the canal to the utricle. This position is also maintained for five minutes.

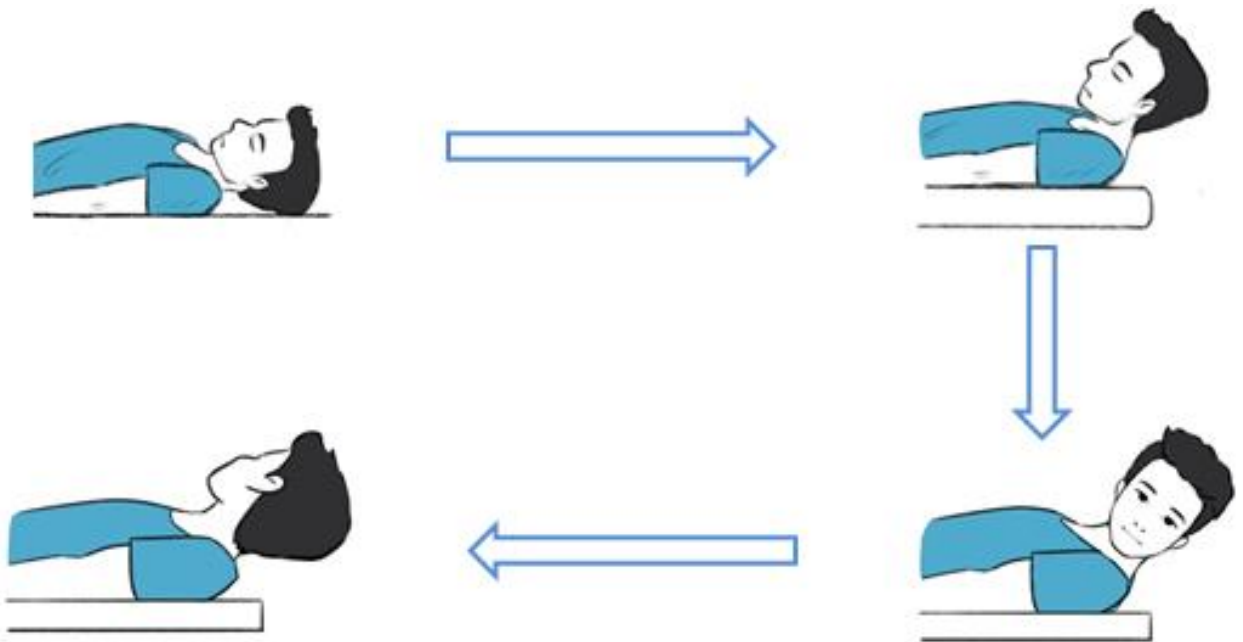


Figure 4.10: Figure showing different positions of the Liberatory maneuver

The subject is asked to avoid lying down and avoid shaking their head for 48 hours as post maneuver restriction. This maneuver should not be used on subjects with cervical issues, neck problems, and vertebrobasilar insufficiency.



#### 4.9 Square wave Maneuver (Yacovino et al., 2021):

The square wave maneuver incorporates Frenzel goggles (or Video oculography) to monitor the nystagmus. This maneuver is performed to change the apogeotropic type of nystagmus into a geotropic type. This maneuver is carried out in the following steps:

- The maneuver starts with the subject in a supine position wearing the Frenzel goggles with their head ventroflexed by 20-30 degrees from the bed/table with the support of the clinician's hand.
- In the next step, the subject is turned 90 degrees towards the affected side. Turning towards the affected side causes deflection of the cupula, which causes vertigo and nystagmus.
- Once the nystagmus reaches its maximum velocity the subject should be turned to the opposite side that is 180-degrees. Due to this movement, the otoconia debris gets detached from the cupula. In this position, a reverse nystagmus is observed.
- Again one should monitor the nystagmus, and when it reaches the maximum, a 180 degree turn to the opposite side is carried out.

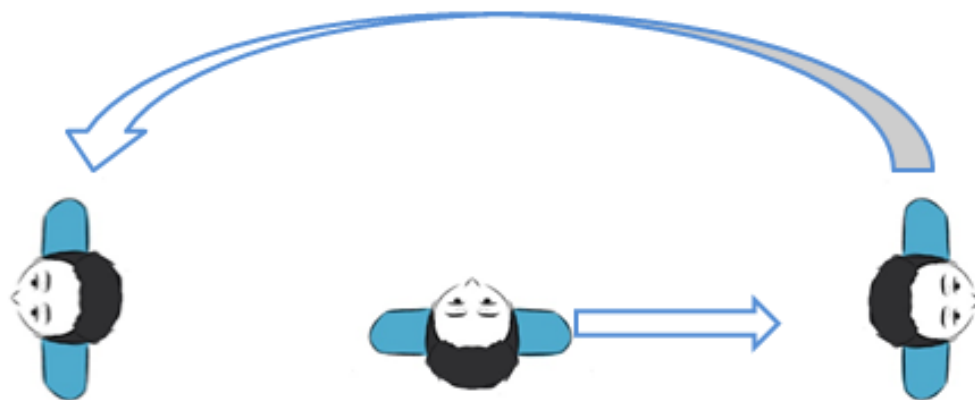


Fig 4.11: Figure showing different positions of the Square wave maneuver

The maneuver is repeated until there is a shift of the apogeotropic to the geotropic form that is if there is a change in the direction of the nystagmus or if the symptoms, nystagmus and vertigo are not elicited after a provoking position. The Barbecue maneuver can be used after this maneuver to free the horizontal canal from otoconia debris. The post maneuver restrictions are not recommended after the maneuver. This maneuver can also be used on subjects with limited neck mobility.

#### **4.10 Forced Prolonged position** (Vannucchi et al., 1997):

The forced prolonged position consists of a single position that is maintained by the subject for a certain prolonged amount of time. It can be used for canalithiasis (geotropic type) of the horizontal semicircular canal BPPV.

- The subject is instructed to lie supine on a bed, turn the head or the whole body towards the healthy side, and maintain this position for 12 hours. If the subject has to get up between the 12 hours period, they should go back to the same position after getting up.



Fig 4.12: Figure showing different positions of the Forced Prolonged position

During this maneuver, the affected ear is uppermost so due to the force of gravity the otoconia debris comes out of the canal and into the vestibule. This maneuver has only one step and is easy to understand, can be easily memorized by individuals. However, as

the subjects have to maintain the position for an extended period, it can be challenging for the patients with cervical issues or obesity. A modification of FPP with the subject lying to the weaker side can be used for all subtypes of HC-BPPV (Chiou et al., 2005).

#### **4.11 Zuma Maneuver (Zuma, 2016):**

The Zuma maneuver is carried out in individuals with an apogeotropic variant of HC-BPPV. It is carried out with the following steps:

- First, the subject is made to sit on the patient's bed with both legs down.
- Next, the subject is lied down towards the affected side briskly. This position is held for 3 minutes. The brisk movement causes the otoconia to detach from the cupula.
- In the third step, the subject's head is rotated towards the ceiling and held in the same position for 3 minutes which helps to bring the otoconia debris towards the utricle.
- Following this step, the subject moves his/her body into dorsal decubitus with the head turned 90 degrees towards the unaffected side. This position is again held for 3 minutes. Here the otoconia particles come closest to the utricle with high chances of it falling into the utricle.
- Lastly, the subject's head is tilted forward slightly, causing the otoconia particles to move into the utricle and get stuck there.
- The subject can then be slowly returned to a sitting position.

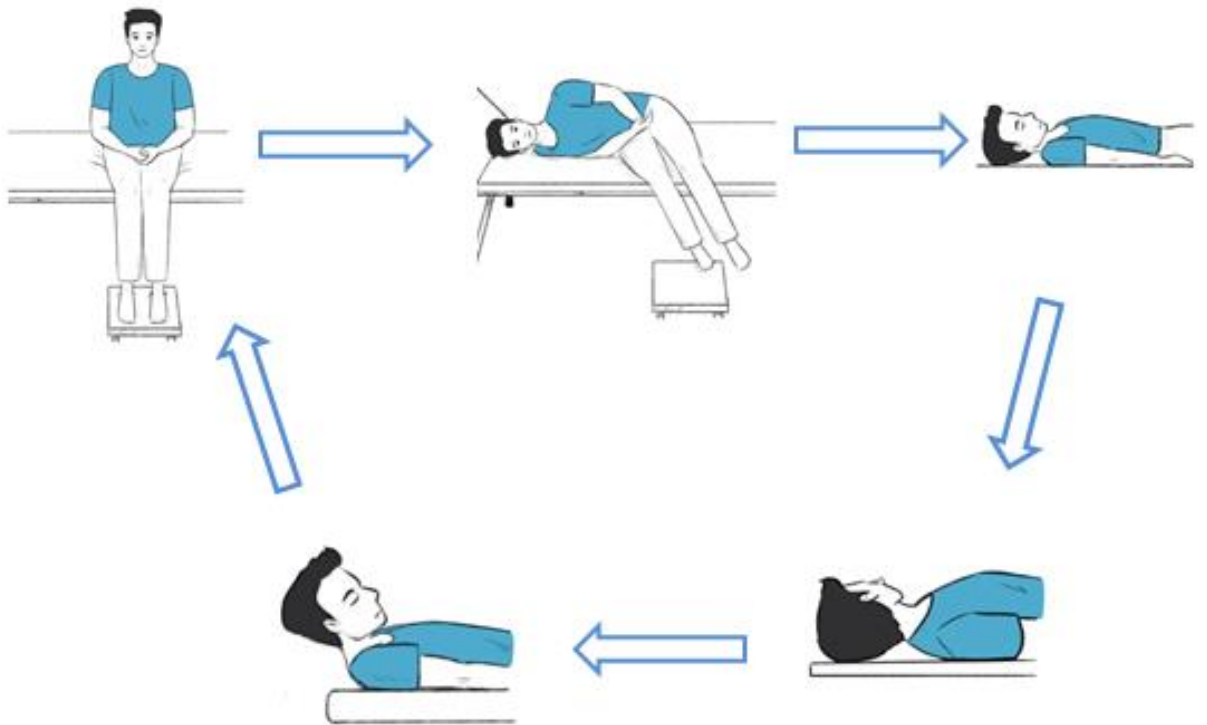


Fig 4.13: Figure showing different positions of the Zuma maneuver

This maneuver can be performed in individuals with cervical problems, mobility issues, obesity, and advancing age, especially when compared to maneuvers that require rotation of the whole body.

**QUESTIONS FOR HC-BPPV REPOSITIONING MANEUVERS:**

1. In the Gufoni maneuver, the subject is brought to a..... position in geotropic type and..... position in apogeotropic type following the seated position.
  - a. Prone and supine
  - b. Sidelying position in affected and sidelying position in unaffected side.
  - c. Supine and prone
  - d. Sidelying position in unaffected and sidelying position in affected side.
2. What modification can be done in subjects with mobility issues in the Barrel roll?
  - a. The position can be changed to complete a full 360° turn.
  - b. The position can be changed to complete a 180° turn.
  - c. The position can be changed to complete a 90° turn.
  - d. The position can be changed to complete a 135° turn.
3. The Kurtzer Hybrid Maneuver is a combination of:
  - a. Gufoni, Appiani and Casani
  - b. Gufoni, Appiani and Epley
  - c. Lempert, Appiani and Casani
  - d. Zuma, Appiani and Casani
4. Each of the head rotation should be carried out ..... time in Barbecue roll.
  - a. Within 1 second
  - b. Within 2 second
  - c. Within 0.5 second
  - d. Between 0.5 to 1 second.
5. When is the position changed in Square wave Maneuver?

- a. After the nystagmus ceases plus 10 seconds.
  - b. Using the Frenzel glasses when the nystagmus reaches its lowest velocity.
  - c. After 30-60 seconds.
  - d. Using the Frenzel glasses when the nystagmus reaches its highest velocity.
6. The forced prolonged position consists of ..... position for ..... time.
- a. Turning the whole body towards the healthy side for 12 hours.
  - b. Turning the whole body towards the unhealthy side for 12 hours.
  - c. Turning the whole body towards the healthy side for 24 hours.
  - d. Turning the whole body towards the unhealthy side for 24 hours.
7. The second position of the Li's maneuver that is side-lying on the unaffected side has to be sustained for.....
- a. 30 seconds
  - b. 4 minutes
  - c. 1 minute
  - d. 5 minutes
8. For the apogeotropic type of HC-BPPV in the Appiani maneuver, the subject is brought to..... position:
- a. Sidelying position towards the affected side.
  - b. Sidelying position towards the unaffected side.
  - c. Prone
  - d. Supine
9. .... does not require the clinician to identify the affected side:
- a. Barbecue roll

- b. Appiani maneuver
  - c. Gufoni maneuver
  - d. Kurtzer Hybrid Maneuver
10. The head is turned towards the healthy side by ..... in the Vannucchi-Asprella maneuver.
- a. 90 degrees
  - b. 45 degrees
  - c. 60 degrees
  - d. 180 degrees
11. .... is the first step in Liberatory maneuver.
- a. Supine with head hanging and below the bed.
  - b. Prone with head hanging out of the bed
  - c. Head is lifted by 30 degrees above from the bed
  - d. Patient is brought to a supine position.
12. Each position has to be maintained for ..... in the Zuma maneuver.
- a. 30 seconds
  - b. 1 minute
  - c. 2 minutes
  - d. 3 minutes

## Chapter-V

### Maneuvers for the treatment of Anterior canal BPPV

The anterior canal BPPV is the rarest variant of BPPV. AC-BPPV accounts for about 1 to 2% of the total BPPV cases. Canalithiasis is the pathophysiology behind the AC-BPPV. The most prominent feature is vertical down beating nystagmus with a torsional component which is also seen in central pathology hence it is important to diagnose the individual with caution (Anagnostou et al., 2015). The repositioning maneuvers have been reported to be an effective treatment for AC-BPPV so it is also used to differentially diagnose it against central lesions as the symptoms disappear immediately after the maneuver in case of AC-BPPV (Von Brevern et al., 2015). The Dix Hallpike test can be done to diagnose this condition. Following features can be seen in AC-BPPV (Von Brevern et al., 2015):

- Reoccurring episodes of vertigo/ dizziness provoked by positions such as lying down and turning over in the supine position.
- Positional nystagmus induced while performing Dix Hallpike test.
- Down beating vertical nystagmus with absent or short latency.
- The attack lasts less than a minute.
- The condition should not be characteristic of other disorders.



### **5.1 Garaycochea Maneuver** (Garaycochea et al., 2020):

The Garaycochea maneuver requires the affected side to be known. It uses gravitational force and inertia to eliminate the debris out of the anterior semicircular canal. This maneuver is carried out in the following steps:

- The first position starts with the subject in a sitting position with the back vertical and straight at 0 degrees. Next, the head is bowed forward by 45 degrees and rotated towards the unaffected side. This brings the anterior canal of the affected side and the unaffected side's posterior canal into a sagittal plane.
- Next, the patient has to be bent quickly forward by 90 degrees via flexion of hips and lumbar spine such that his/her head reaches till the height of their knees, and this has to be maintained for a minute. This will displace the otoconia to the lowest gravitational point of the anterior canal.
- Then the subject's head is rotated towards the affected side. This moves the otoconia slowly towards the common crus. The body is still in a bent position, similar to the second step. This position is to be maintained for a minute.
- Maintaining the head rotated to the affected side, the subject is brought to a sitting position with the back straight getting the otoconia into the common crus.
- Lastly, the head is brought slowly to the midline and into a neutral position that causes the otoconia to move into the utricle.

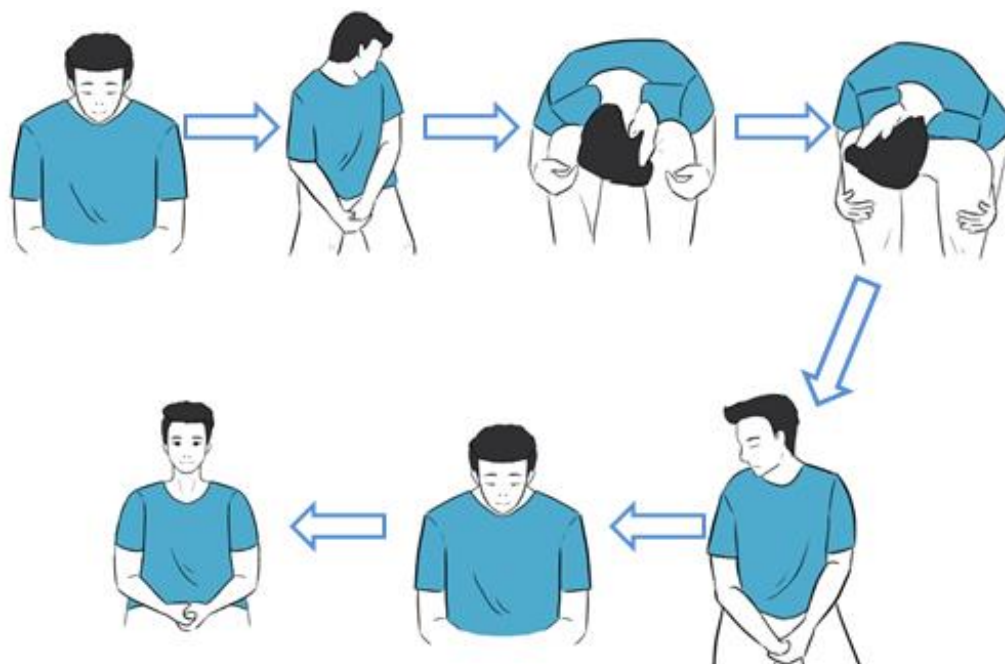


Figure 5.1: Figure showing different positions of the Garaycochea Maneuver

It is recommended to repeat the maneuver until the symptoms disappear. This maneuver can be performed in older subjects and subjects with neck problems, however, it might be challenging for obese subjects. It is also helpful to convert the apogeotropic variety of the posterior canal, which also shows down beating torsional nystagmus into the geotropic variety.

### 5.2 Kim's Maneuver (Kim et al., 2005):

- The maneuver starts with the subject in a seated position on the patient's bed.
- The subject's head is turned towards the unaffected side by 45°.
- Keeping the head turned, the subject is brought to a supine position with their head hanging off the end of the bed by 45°. This is maintained for 2 minutes.
- The head is brought to a supine position from the hanging position, with the head still turned to the unaffected side. This is maintained for 1 minute.

- The subject is brought to a seated position head straight and chin tilted down by 30°.

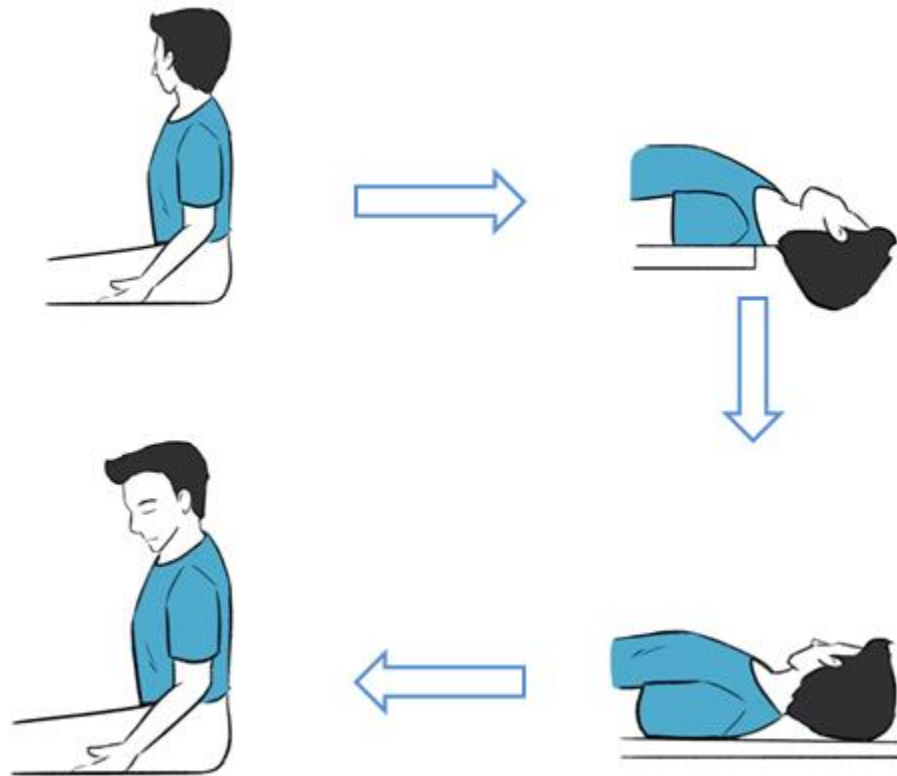


Figure 5.2: Figure showing different positions of the Kim's Maneuver

The maneuver can be reapplied until the symptoms completely disappear.

### 5.3 Prolonged forced position procedure (Crevits, 2004):

This maneuver requires the subject to be hospitalized and takes 24 hours to complete. The rationale behind it is that as the subject lies in the proposed position, the anterior canal that is affected is uppermost and almost in a gravitationally vertical position. So when the position is prolonged, the otoconia particles of the canal come out of the canal because of gravity. The maneuver has two steps:

- The maneuver starts with the subject in a seated position.

- The subject has to be moved rapidly to a supine position with their head bend backward as far as possible such that the vertex is around  $60^\circ$  below the horizontal. This position is maintained for 30 minutes. In this head position, the otoconia debris moves to the upper part of the anterior canal.
- Next, the subject's head is brought forward as far as possible with vertex near the vertical. To sustain this position, the head is held using a pulley system, and the subject is not supposed to stand up for 24 hours. This position causes the otoconia debris to come out of the canal and into the vestibule.
- After 24 hours, the subject is brought to a sitting position with their head straight for a few minutes such that it helps the debris to further go into the utricle.

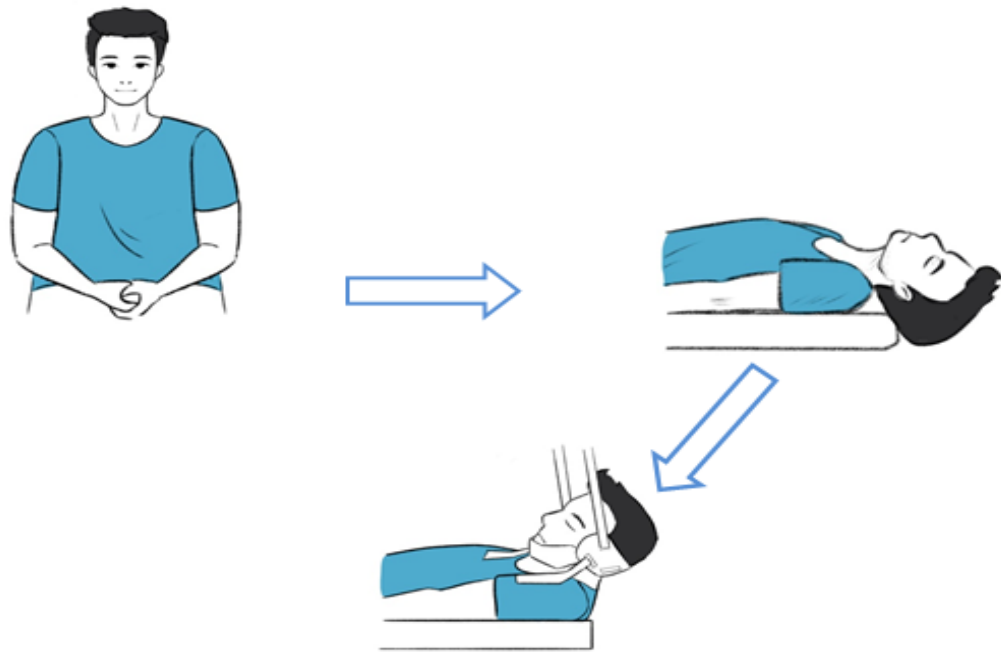


Figure 5.3: Figure showing different positions of the Prolonged forced position procedure

Following the maneuver, a diagnostic test should be done to determine its efficacy. No post maneuver restrictions are recommended after this maneuver. This

maneuver does not require knowledge of the pathological side and can be done when the clinician is not sure about which side is affected. As the maneuver requires the subject to maintain the same position for 24 hours, it can cause neck stiffness, so myorelaxation is recommended. Also, the head should be placed correctly as indicated because if it is too front or too back, the debris can go into other semicircular canals instead of utricle hence, the use of a pulley system is suggested.

#### **5.4 Reversed CRP maneuver (Honrubia et al., 1999):**

The reverse Epley maneuver, also known as the reverse CRP can be used for the canalithiasis of the anterior semicircular canal and is one of the first maneuvers that were described for AC-BPPV. Here, the positions are similar to those used in contralateral posterior canalithiasis (Korres et al., 2010). The maneuver is carried out in the following steps:

- The maneuver starts with the subject in a seated position.
- The head of the subject is turned 45° towards the healthy side.
- The subject is then quickly brought to a supine position and the head slightly hanging out of the bed with it turned to the healthy side.
- Next, the head has to be rotated slowly towards the affected side ear.
- The subject is then brought to a side-lying position, with the head turned toward the affected side by 45° and facing towards the floor.
- Lastly, he/she is brought back to a sitting position.

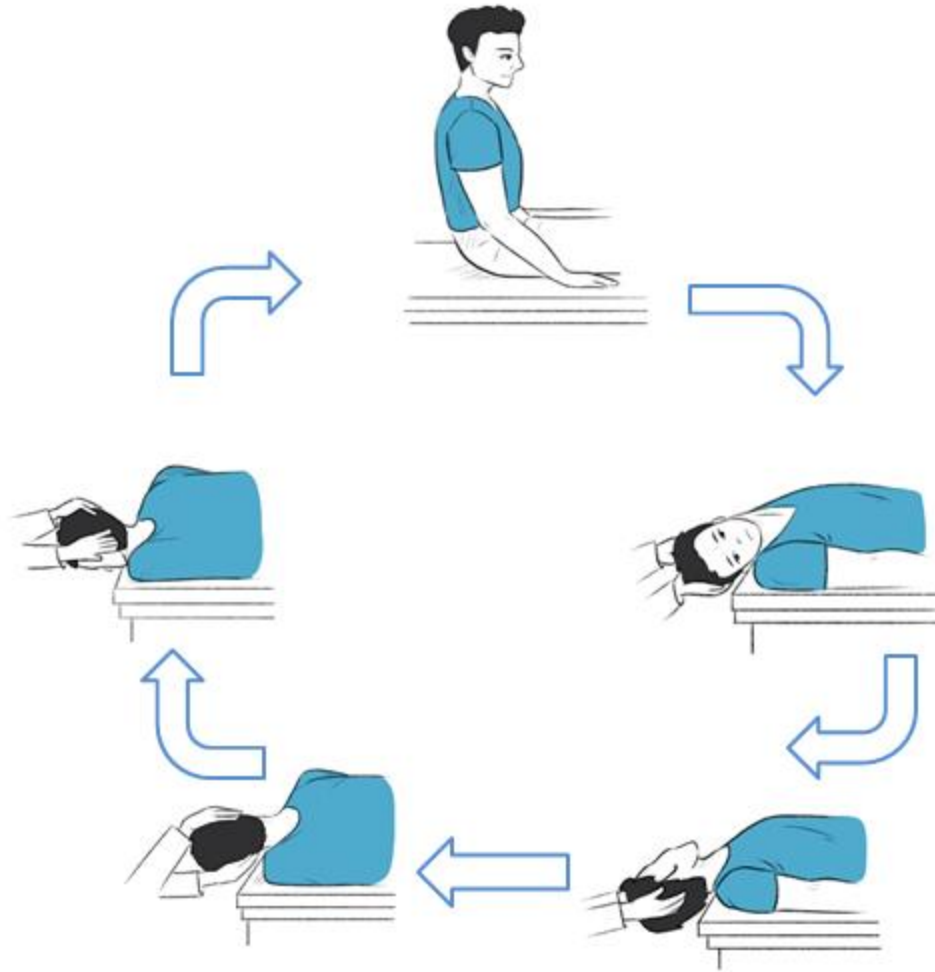


Figure 5.4.: Figure showing different positions of the Reversed CRP maneuver

Numerous clinicians have used this maneuver; however, there is a dearth of information on the efficacy, the timing of the steps, and its outcome (Korres et al., 2010). A modified epley's maneuver also was introduced, which is the opposite of reverse CRP with the procedure starting from the head turned to the affected side (Jackson et al., 2007).

### 5.5 Short CRP (Rivas et al., 2020):

The short CRP is a modification of the traditional CRP and was tested using a 3D biochemical model of the semicircular canals. The short CRP comprises of the following steps:

- The maneuver starts with the subject in a seated position.
- The head of the subject is turned towards the affected side by 45° .
- Next, the head hangs below the horizon by 40 degrees and towards the affected side by 45 degrees.
- With the head hanging below it is turned towards the unaffected side by 45 degrees.
- Lastly, the subject returns to a sitting position.

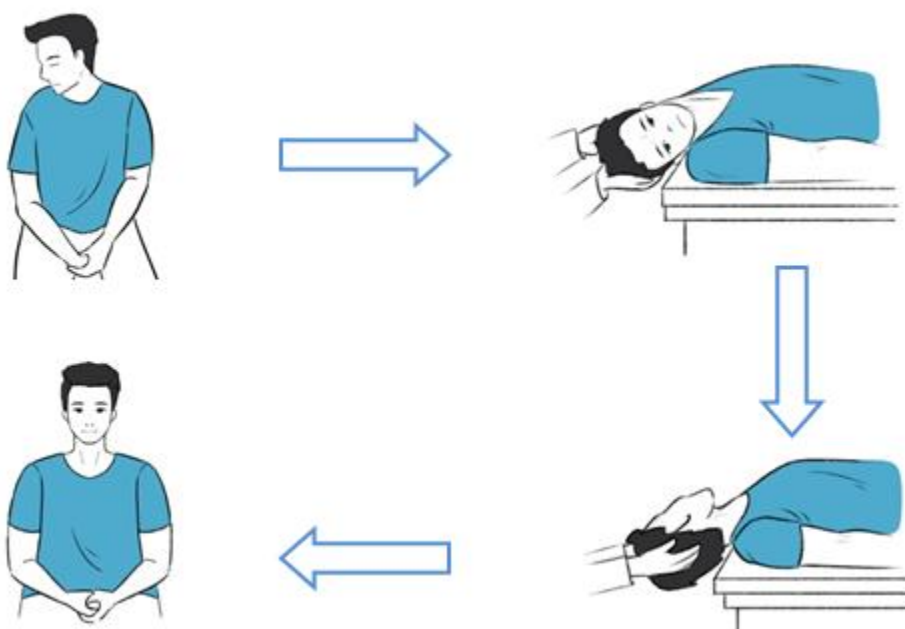


Figure 5.5: Figure showing different positions of the Short CRP maneuver

This maneuver requires the affected side to be known by the clinician. It is recommended for subjects with neck mobility issues as the movements are not very

extensive. These positions were performed on the 3D model and it had proven to eliminate the otoconia debris from the canals however, effectively it is yet to be tested on human subjects.

#### **5.6 Yacovino Maneuver** (Yacovino et al., 2009):

The Yacovino maneuver is a rapid and less cumbersome maneuver for the canalithiasis of the anterior semicircular canal. This maneuver does not require the clinician to know the side that is affected. It is carried out in the following steps:

- The maneuver starts with the subject in a seated position.
- The subject is brought to a supine position with the head hanging out of the bed and below 30 degrees of the horizon. The otoconia move away from the anterior canal cupula. If the individual is unable to bend the head 30 degrees, a tilting table can be used.
- Next, with the subject in the supine position, the head is brought forward forming a chin to chest position. The otoconia moves towards the common crus.
- Lastly, the subject is brought back to a seated position letting the otoconia move out of the common crus into the utricle.



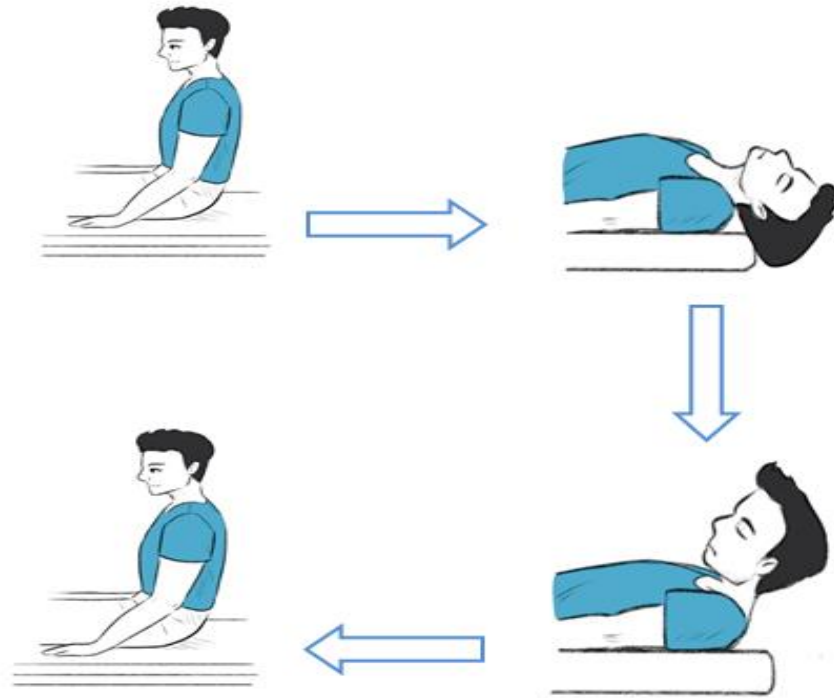


Figure 5.6: Figure showing different positions of the Yacovino maneuver

Each position should be maintained for at least 30 seconds, and the nystagmus and vertigo should cease before moving to the next position. If the maneuver is not successful the first time, it can be repeated, and the duration the subject stays in the head hanging position can be increased. As this maneuver does not require the affected side to be known, it can be used in individuals whose torsional component is not evident, and the affected side cannot be determined.

**QUESTIONS FOR AC-BPPV REPOSITIONING MANEUVERS:**

1. The anterior canal BPPV is characterized by ..... nystagmus.
  - a. Up beating torsional
  - b. Down beating torsional
  - c. Geotropic
  - d. Apogeotropic
  
2. The Garaycochea maneuver can be used in.....
  - a. AC-BPPV & Apogeotropic variety of PC-BPPV
  - b. AC-BPPV & all type of PC-BPPV
  - c. AC-BPPV & Apogeotropic variety of HC-BPPV
  - d. AC-BPPV & Geotropic variety of HC-BPPV
  
3. How long is the prolonged force position procedure carried out for?
  - a. 48 hours
  - b. 12 hours
  - c. 36 hours
  - d. 24 hours
  
4. Which maneuver requires the individual with BPPV to be hospitalized?
  - a. Kim's maneuver
  - b. Prolonged force position procedure
  - c. Yacovino's maneuver
  - d. Reverse CRP maneuver

5. The reversed CRP head is first turned to ..... and in modified Epley turned to.....
  - a. Affected and unaffected
  - b. Unaffected and downward
  - c. Front and affected
  - d. Unaffected and affected
  
6. .... maneuver may have neck stiffness as a side effect due to its duration.
  - a. Prolonged force position procedure
  - b. Kim maneuver
  - c. Yacovino maneuver
  - d. Reverse CRP maneuver
  
7. In case the clinician does not know the affected side which maneuvers can be applied?
  - a. Prolonged force position procedure
  - b. Yacovino maneuver
  - c. Reverse CRP maneuver
  - d. Prolonged force position procedure & Yacovino maneuver
  
8. When the head hangs below and out of the examination bed how does it affect the otoconia debris?
  - a. It moves towards the cupula
  - b. It moves away from the cupula
  - c. It moves away from the common crus
  - d. It comes out of the common crus

9. Prolonged force position uses the pulley system to.....
- a. Change the position
  - b. Prevent the subject from injuries
  - c. Maintain the position for a long time
  - d. Prevent vertigo during change in position
10. The Kim maneuver starts with subject in.....
- a. Supine position
  - b. Prone position
  - c. Head turned to affected side
  - d. Head turned to unaffected side.
11. The short CRP was tested on.....
- a. 3D biochemical model of the semicircular canals.
  - b. Subjects with AC-BPPV
  - c. Subjects with PC-BPPV
  - d. Subjects with AC-BPPV whose affected side could not be determined.
12. During the supine chin to chest position of the Yacovino's maneuver, the otoconia:
- a. Comes out of the common crus
  - b. Moves towards the common crus
  - c. Moves towards the cupula
  - d. Moves into the utricle

## Chapter-VI

### Post-maneuver Restrictions

The post-maneuver restrictions are certain physical-movement restrictions that are advised to the individual after the maneuver is carried out to prevent the re-entering of otoconia debris into the semicircular canal. With different types of available maneuvers, the instruction on the post-maneuver restriction also varies. Refraining from lying down, avoiding certain head movements, avoiding brisk movements, etc. are some of the examples of post-maneuver restrictions (Roberts et al., 2005).

The duration these restrictions are to be followed also varies from 24 hours, 48 hours to up until a week. Epley (1992) recommended the patients to keep his/ her head relatively up such that the debris does not come back into the canal for at least 48 hours after the completion of his CRP. In the case of the Semont liberatory maneuver, the patient was advised against lying down for 48 hours, refrained from sleeping on the affected side, and fast movements of the head for a week (Semont et al., 1988). Similarly, after the completion of the Liberatory maneuver for HC-BPPV, it was advised to refrain from lying down and not to shake head for 48 hours (De la Meilleure et al, 1996).

The rationale behind these restrictions was to prevent the otoconia debris to re-enter inside the semicircular canal however many subsequent studies advise against it stating the restrictions to be unnecessary. Marciano and Marcelli (2002) studied subjects with and without the post-maneuver restrictions in whom CRP/ SLM was performed and found similar treatment outcomes in both groups. Likewise in a comparative study of the Epley's maneuver with and without the post-maneuver restrictions, it was found that the subjects without restrictions had better posturography measures suggesting a negative

impact of the post-maneuver restrictions. Roberts et. al. (2005) have stated that there is no improvement in the efficacy of repositioning maneuvers with the use of post-maneuver restrictions.

**Answers for Multiple choice Questions**

Answers pertaining to PC-BPPV	Answers pertaining to HC-BPPV	Answers pertaining to AC-BPPV
1. C	1. D	1. B
2. C	2. D	2. A
3. A	3. A	3. D
4. B	4. C	4. B
5. A	5. D	5. D
6. C	6. A	6. A
7. B	7. B	7. D
8. D	8. A	8. B
9. B	9. D	9. C
10. D	10. A	10. D
11. A	11. C	11. A
12. B	12. D	12. B

## References

- Agrawal, Y., Ward, B. K., & Minor, L. B. (2013). Vestibular dysfunction: prevalence, impact and need for targeted treatment. *Journal of vestibular research: equilibrium & orientation*, 23(3), 113–117. <https://doi.org/10.3233/VES-130498>
- Al Saif, A. A., Alem, H. B., & Alsenany, S. (2012). Efficiency of the deep head hanging maneuver for anterior canal benign paroxysmal positional vertigo. *Journal of Physical Therapy Science*, 24(11), 1191-1193. <https://doi.org/10.1589/jpts.24.1191>
- Anagnostou, E., Kouzi, I., & Spengos, K. (2015). Diagnosis and Treatment of Anterior-Canal Benign Paroxysmal Positional Vertigo: A Systematic Review. *Journal of clinical neurology (Seoul, Korea)*, 11(3), 262–267. <https://doi.org/10.3988/jcn.2015.11.3.262>
- Asprella Libonati G. (2005). Diagnostic and treatment strategy of lateral semicircular canal canalolithiasis. *Acta otorhinolaryngologica Italica : organo ufficiale della Societa italiana di otorinolaringologia e chirurgia cervico-facciale*, 25(5), 277–283. PMID: 16602326
- Atacan, E., Sennaroglu, L., Genc, A., & Kaya, S. (2001). Benign paroxysmal positional vertigo after stapedectomy. *The Laryngoscope*, 111(7), 1257–1259. <https://doi.org/10.1097/00005537-200107000-00021>
- Baloh, R. W. (1994). Horizontal benign positional vertigo. *Neurology*, 44(11), 2214-2214. <https://doi.org/10.1212/WNL.44.11.2214>



- Baloh, R. W., Honrubia, V., & Jacobson, K. (1987). Benign positional vertigo: clinical and oculographic features in 240 cases. *Neurology*, *37*(3), 371–378. <https://doi.org/10.1212/wnl.37.3.371>
- Bashir, K., Yousafzai, M. T., & Cameron, P. (2016). The Bashir manoeuvre: A new single treatment for all subtypes of benign paroxysmal positional vertigo. *International Journal of Therapy and Rehabilitation*, *23*(12), 600-603. <https://doi.org/10.12968/ijtr.2016.23.12.600>
- Benecke, H., Agus, S., Kuessner, D., Goodall, G., & Strupp, M. (2013). The Burden and Impact of Vertigo: Findings from the REVERT Patient Registry. *Frontiers in neurology*, *4*, 136. <https://doi.org/10.3389/fneur.2013.00136>
- Bhattacharyya, N., Gubbels, S. P., Schwartz, S. R., Edlow, J. A., El-Kashlan, H., Fife, T., Holmberg, J. M., Mahoney, K., Hollingsworth, D. B., Roberts, R., Seidman, M. D., Steiner, R. W., Do, B. T., Voelker, C. C., Waguespack, R. W., & Corrigan, M. D. (2017). Clinical Practice Guideline: Benign Paroxysmal Positional Vertigo (Update). *Otolaryngology--head and neck surgery: official journal of American Academy of Otolaryngology-Head and Neck Surgery*, *156*(3\_suppl), S1–S47. <https://doi.org/10.1177/0194599816689667>
- Campbell, B., Kimura, K., Yawn, R., & Bennett, M. (2019). Pathophysiology and Diagnosis of BPPV. *Diagnosis and Treatment of Vestibular Disorders*, 141-150. [https://doi.org/10.1007/978-3-319-97858-1\\_11](https://doi.org/10.1007/978-3-319-97858-1_11)
- Casani, A. P., Nacci, A., Dallan, I., Panicucci, E., Gufoni, M., & Sellari-Franceschini, S. (2011). Horizontal semicircular canal benign paroxysmal positional vertigo:

- effectiveness of two different methods of treatment. *Audiology & neuro-otology*, 16(3), 175–184. <https://doi.org/10.1159/000317113>
- Chiou, W. Y., Lee, H. L., Tsai, S. C., Yu, T. H., & Lee, X. X. (2005). A single therapy for all subtypes of horizontal canal positional vertigo. *The Laryngoscope*, 115(8), 1432–1435. <https://doi.org/10.1097/01.mlg.0000168092.91251.d3>
- Ciniglio Appiani, G., Catania, G., & Gagliardi, M. (2001). A liberatory maneuver for the treatment of horizontal canal paroxysmal positional vertigo. *Otology & neurotology : official publication of the American Otological Society, American Neurotology Society [and] European Academy of Otology and Neurotology*, 22(1), 66–69. <https://doi.org/10.1097/00129492-200101000-00013>
- Ciniglio Appiani, G., Catania, G., Gagliardi, M., & Cuiuli, G. (2005). Repositioning maneuver for the treatment of the apogeotropic variant of horizontal canal benign paroxysmal positional vertigo. *Otology & neurotology : official publication of the American Otological Society, American Neurotology Society [and] European Academy of Otology and Neurotology*, 26(2), 257–260. <https://doi.org/10.1097/00129492-200503000-00022>
- Cohen H. S. (2004). Side-lying as an alternative to the Dix-Hallpike test of the posterior canal. *Otology & neurotology : official publication of the American Otological Society, American Neurotology Society [and] European Academy of Otology and Neurotology*, 25(2), 130–134. <https://doi.org/10.1097/00129492-200403000-00008>

- Cohen, H. S., & Jerabek, J. (1999). Efficacy of treatments for posterior canal benign paroxysmal positional vertigo. *The Laryngoscope*, *109*(4), 584–590. <https://doi.org/10.1097/00005537-199904000-00012>
- Crevits L. (2004). Treatment of anterior canal benign paroxysmal positional vertigo by a prolonged forced position procedure. *Journal of neurology, neurosurgery, and psychiatry*, *75*(5), 779–781. <https://doi.org/10.1136/jnnp.2003.025478>
- D'Albora Rivas, R., Teixido, M., Casserly, R. M., & Mónaco, M. J. (2020). Short CRP for Anterior Canalithiasis: A New Maneuver Based on Simulation With a Biomechanical Model. *Frontiers in neurology*, *11*, 857. <https://doi.org/10.3389/fneur.2020.00857>
- De la Meilleure, G., Dehaene, I., Depondt, M., Damman, W., Crevits, L., & Vanhooren, G. (1996). Benign paroxysmal positional vertigo of the horizontal canal. *Journal of neurology, neurosurgery, and psychiatry*, *60*(1), 68–71. <https://doi.org/10.1136/jnnp.60.1.68>
- Epley J. M. (1992). The canalith repositioning procedure: for treatment of benign paroxysmal positional vertigo. *Otolaryngology--head and neck surgery : official journal of American Academy of Otolaryngology-Head and Neck Surgery*, *107*(3), 399–404. <https://doi.org/10.1177/019459989210700310>
- Epley J. M. (2001). Human experience with canalith repositioning maneuvers. *Annals of the New York Academy of Sciences*, *942*, 179–191. <https://doi.org/10.1111/j.1749-6632.2001.tb03744.x>

- Epley, J. M. (1997). Caveats in particle repositioning for treatment of canalithiasis (BPPV). *Operative Techniques in Otolaryngology-Head and Neck Surgery*, 8(2), 68-76. [https://doi.org/10.1016/S1043-1810\(97\)80005-X](https://doi.org/10.1016/S1043-1810(97)80005-X)
- Faldon, M. E., & Bronstein, A. M. (2008). Head accelerations during particle repositioning manoeuvres. *Audiology & neuro-otology*, 13(6), 345–356. <https://doi.org/10.1159/000136153>
- Fife T. D. (2009). Benign paroxysmal positional vertigo. *Seminars in neurology*, 29(5), 500–508. <https://doi.org/10.1055/s-0029-1241041>
- Foster, C. A., Ponnapan, A., Zaccaro, K., & Strong, D. (2012). A comparison of two home exercises for benign positional vertigo: Half somersault versus Epley Maneuver. *Audiology and Neurotology Extra*, 2(1), 16-23. <https://doi.org/10.1159/000337947>
- Gans, RE., Darren Kurtzer, & McLeod, H. (2017). New horizontal canal benign paroxysmal positional vertigo treatment: kurtzer hybrid maneuver. *Global Journal of Otolaryngol*, 6(3), 1-5. [10.19080/GJO.2017.06.555686](https://doi.org/10.19080/GJO.2017.06.555686)
- Garaycochea, O., Pérez-Fernández, N., & Manrique-Huarte, R. (2020). A novel maneuver for diagnosis and treatment of torsional-vertical down beating positioning nystagmus: anterior canal and apogeotropic posterior canal BPPV. *Brazilian journal of otorhinolaryngology*, S1808-8694(20)30175-0. Advance online publication. <https://doi.org/10.1016/j.bjorl.2020.09.009>
- Gross, E. M., Ress, B. D., Viirre, E. S., Nelson, J. R., & Harris, J. P. (2000). Intractable benign paroxysmal positional vertigo in patients with Meniere's disease. *The*

*Laryngoscope*, 110(4), 655–659. <https://doi.org/10.1097/00005537-200004000-00022>

Gufoni, M., Mastrosimone, L., & Di Nasso, F. (1998). Trattamento con manovra di riposizionamento per la canalolitiasi orizzontale [Repositioning maneuver in benign paroxysmal vertigo of horizontal semicircular canal]. *Acta otorhinolaryngologica Italica : organo ufficiale della Societa italiana di otorinolaringologia e chirurgia cervico-facciale*, 18(6), 363–367.

Hall, S. F., Ruby, R. R., & McClure, J. A. (1979). The mechanics of benign paroxysmal vertigo. *The Journal of Otolaryngology*, 8(2), 151–158. PMID: 430582

Hilton, M. P., & Pinder, D. K. (2014). The Epley (canalith repositioning) manoeuvre for benign paroxysmal positional vertigo. *The Cochrane database of systematic reviews*, (12), CD003162. <https://doi.org/10.1002/14651858.CD003162.pub3>

Honrubia, V., Baloh, R. W., Harris, M. R., & Jacobson, K. M. (1999). Paroxysmal positional vertigo syndrome. *The American journal of otology*, 20(4), 465–470. PMID: 10431888

Hülse, R., Biesdorf, A., Hörmann, K., Stuck, B., Erhart, M., Hülse, M., & Wenzel, A. (2019). Peripheral Vestibular Disorders: An Epidemiologic Survey in 70 Million Individuals. *Otology & neurotology : official publication of the American Otological Society, American Neurotology Society [and] European Academy of Otolology and Neurotology*, 40(1), 88–95. <https://doi.org/10.1097/MAO.0000000000002013>

Imai, T., Takeda, N., Ito, M., Sekine, K., Sato, G., Midoh, Y., Nakamae, K., & Kubo, T. (2009). 3D analysis of benign positional nystagmus due to cupulolithiasis in

posterior semicircular canal. *Acta oto-laryngologica*, 129(10), 1044–1049.

<https://doi.org/10.1080/00016480802566303>

Jackson, L. E., Morgan, B., Fletcher, J. C., Jr, & Krueger, W. W. (2007). Anterior canal benign paroxysmal positional vertigo: an underappreciated entity. *Otology & neurotology : official publication of the American Otological Society, American Neurotology Society [and] European Academy of Otology and Neurotology*, 28(2), 218–222.

<https://doi.org/10.1097/01.mao.0000247825.90774.6b>

Kim, Y. K., Shin, J. E., & Chung, J. W. (2005). The effect of canalith repositioning for anterior semicircular canal canalithiasis. *ORL; journal for oto-rhino-laryngology and its related specialties*, 67(1), 56–60. <https://doi.org/10.1159/000084336>

Korres, S., Riga, M., Sandris, V., Danielides, V., & Sismanis, A. (2010). Canalithiasis of the anterior semicircular canal (ASC): treatment options based on the possible underlying pathogenetic mechanisms. *International journal of audiology*, 49(8), 606–612. <https://doi.org/10.3109/14992021003753490>

Lempert, T., & Tiel-Wilck, K. (1996). A positional maneuver for treatment of horizontal-canal benign positional vertigo. *The Laryngoscope*, 106(4), 476–478.

<https://doi.org/10.1097/00005537-199604000-00015>

Li, J. C., Li, C. J., Epley, J., & Weinberg, L. (2000). Cost-effective management of benign positional vertigo using canalith repositioning. *Otolaryngology--head and neck surgery : official journal of American Academy of Otolaryngology-Head and Neck Surgery*, 122(3), 334–339. <https://doi.org/10.1067/mhn.2000.100752>

- Li, J., Guo, P., Tian, S., Li, K., & Zhang, H. (2015). Quick repositioning maneuver for horizontal semicircular canal benign paroxysmal positional vertigo. *Journal of otology*, *10*(3), 115–117. <https://doi.org/10.1016/j.joto.2015.11.005>
- Liu, Y., Wang, W., Zhang, A. B., Bai, X., & Zhang, S. (2016). Epley and Semont maneuvers for posterior canal benign paroxysmal positional vertigo: A network meta-analysis. *The Laryngoscope*, *126*(4), 951–955. <https://doi.org/10.1002/lary.25688>
- Mandalà, M., Pepponi, E., Santoro, G. P., Cambi, J., Casani, A., Faralli, M., Giannoni, B., Gufoni, M., Marcelli, V., Trabalzini, F., Vannucchi, P., & Nuti, D. (2013). Double-blind randomized trial on the efficacy of the Gufoni maneuver for treatment of lateral canal BPPV. *The Laryngoscope*, *123*(7), 1782–1786. <https://doi.org/10.1002/lary.23918>
- Maranhão, E. T., Whitney, S. L., & Maranhão-Filho, P. (2018). Tumarkin-like phenomenon as a sign of therapeutic success in benign paroxysmal positional vertigo. *Arquivos de neuro-psiquiatria*, *76*(8), 534–538. <https://doi.org/10.1590/0004-282X20180073>
- Marciano, E., & Marcelli, V. (2002). Postural restrictions in labyrintholithiasis. *European archives of oto-rhino-laryngology : official journal of the European Federation of Oto-Rhino-Laryngological Societies (EUFOS) : affiliated with the German Society for Oto-Rhino-Laryngology - Head and Neck Surgery*, *259*(5), 262–265. <https://doi.org/10.1007/s00405-001-0445-7>
- Nakayama, M., & Epley, J. M. (2005). BPPV and variants: improved treatment results with automated, nystagmus-based repositioning. *Otolaryngology--head and neck*

*surgery : official journal of American Academy of Otolaryngology-Head and Neck Surgery*, 133(1), 107–112. <https://doi.org/10.1016/j.otohns.2005.03.027>

Oghalai, J. S., Manolidis, S., Barth, J. L., Stewart, M. G., & Jenkins, H. A. (2000).

Unrecognized benign paroxysmal positional vertigo in elderly patients. *Otolaryngology--head and neck surgery : official journal of American Academy of Otolaryngology-Head and Neck Surgery*, 122(5), 630–634. <https://doi.org/10.1067/mhn.2000.105415>

Oron, Y., Cohen-Atsmoni, S., Len, A., & Roth, Y. (2015). Treatment of horizontal canal

BPPV: pathophysiology, available maneuvers, and recommended treatment. *The Laryngoscope*, 125(8), 1959–1964. <https://doi.org/10.1002/lary.25138>

Parnes, L. S., Agrawal, S. K., & Atlas, J. (2003). Diagnosis and management of benign

paroxysmal positional vertigo (BPPV). *CMAJ : Canadian Medical Association journal = journal de l'Association medicale canadienne*, 169(7), 681–693. PMID: 14517129

Roberts, R. A., Gans, R. E., & Montaudo, R. L. (2006). Efficacy of a new treatment

maneuver for posterior canal benign paroxysmal positional vertigo. *Journal of the American Academy of Audiology*, 17(8), 598–604.

<https://doi.org/10.3766/jaaa.17.8.6>

Roberts, R. A., Gans, R. E., DeBoodt, J. L., & Lister, J. J. (2005). Treatment of benign

paroxysmal positional vertigo: necessity of postmaneuver patient restrictions. *Journal of the American Academy of Audiology*, 16(6), 357–366.

<https://doi.org/10.3766/jaaa.16.6.4>



- Saberi, A., Nemati, S., Sabnan, S., Mollahoseini, F., & Kazemnejad, E. (2017). A safe-repositioning maneuver for the management of benign paroxysmal positional vertigo: Gans vs. Epley maneuver; a randomized comparative clinical trial. *European archives of oto-rhino-laryngology : official journal of the European Federation of Oto-Rhino-Laryngological Societies (EUFOS) : affiliated with the German Society for Oto-Rhino-Laryngology - Head and Neck Surgery*, 274(8), 2973–2979. <https://doi.org/10.1007/s00405-016-4235-7>
- Sakata, E., Ohtsu, K., & Sakata, H. (2004). Pitfalls in which otolaryngologists often are caught in the diagnosis and treatment of vertigo. *The international tinnitus journal*, 10(1), 31–34. PMID: 15379345
- Schuknecht H. F. (1962). Positional vertigo: clinical and experimental observations. *Transactions - American Academy of Ophthalmology and Otolaryngology. American Academy of Ophthalmology and Otolaryngology*, 66, 319–332. PMID: 13909445
- Semont, A., Freyss, G., & Vitte, E. (1988). Curing the BPPV with a liberatory maneuver. *Advances in oto-rhino-laryngology*, 42, 290–293. <https://doi.org/10.1159/000416126>
- Soto Varela, A., Bartual Magro, J., Santos Pérez, S., Vélez Regueiro, M., Lechuga García, R., Pérez-Carro Ríos, A., & Caballero, L. (2001). Benign paroxysmal vertigo: a comparative prospective study of the efficacy of Brandt and Daroff exercises, Semont and Epley maneuver. *Revue de laryngologie - otologie - rhinologie*, 122(3), 179–183. PMID: 11799859

- Steenerson, R. L., Cronin, G. W., & Marbach, P. M. (2005). Effectiveness of treatment techniques in 923 cases of benign paroxysmal positional vertigo. *The Laryngoscope*, *115*(2), 226–231.  
<https://doi.org/10.1097/01.mlg.0000154723.55044.b5>
- Sundararajan, I., Rangachari, V., Sumathi, V., & Kumar, K. (2011). Epley's manoeuvre versus Epley's manoeuvre plus labyrinthine sedative as management of benign paroxysmal positional vertigo: prospective, randomised study. *The Journal of laryngology and otology*, *125*(6), 572–575.  
<https://doi.org/10.1017/S0022215110002781>
- Swain, S., Behera, I. C., & Sahu, M. C. (2018). Prevalence of Benign Paroxysmal Positional Vertigo: Our experiences at a tertiary care hospital of India. *Egyptian Journal of Ear, Nose, Throat and Allied Sciences*, *19*(3), 87-92.  
[10.21608/EJENTAS.2018.5246.1040](https://doi.org/10.21608/EJENTAS.2018.5246.1040)
- Testa, D., Castaldo, G., De Santis, C., Trusio, A., & Motta, G. (2012). Treatment of horizontal canal benign paroxysmal positional vertigo: a new rehabilitation technique. *The Scientific World Journal*, *2012*, 160475.  
<https://doi.org/10.1100/2012/160475>
- Vannucchi, P. & Giannoni B. (1998). Terapia della vertigine parossistica posizionale del canale semicircolare laterale. Tecniche a confronto. *VII Giornata di Vestibologia Pratica 'La terapia fisica delle vertigini periferiche'* Nuti D, Passali D. editors. CSS Formenti Milano, 61-73.

- Vannucchi, P., Giannoni, B., & Pagnini, P. (1997). Treatment of horizontal semicircular canal benign paroxysmal positional vertigo. *Journal of vestibular research : equilibrium & orientation*, 7(1), 1–6. 10.3233/VES-1997-7101
- Vannucchi, P., Libonati, G. A., & Gufoni, M. (2005). The physical treatment of lateral semicircular canal canalolithiasis. *Audiological Medicine*, 3(1), 52-56. <https://doi.org/10.1080/16513860510029445>
- Von Brevern, M., Bertholon, P., Brandt, T., Fife, T., Imai, T., Nuti, D., & Newman-Toker, D. (2015). Benign paroxysmal positional vertigo: Diagnostic criteria. *Journal of vestibular research: equilibrium & orientation*, 25(3-4), 105–117. <https://doi.org/10.3233/VES-150553>
- Von Brevern, M., Radtke, A., Lezius, F., Feldmann, M., Ziese, T., Lempert, T., & Neuhauser, H. (2007). Epidemiology of benign paroxysmal positional vertigo: a population based study. *Journal of neurology, neurosurgery, and psychiatry*, 78(7), 710–715. <https://doi.org/10.1136/jnnp.2006.100420>
- White, J., Savvides, P., Cherian, N., & Oas, J. (2005). Canalith repositioning for benign paroxysmal positional vertigo. *Otology & neurotology : official publication of the American Otological Society, American Neurotology Society [and] European Academy of Otology and Neurotology*, 26(4), 704–710. <https://doi.org/10.1097/01.mao.0000178128.66482.7e>
- Yacovino, D. A., Hain, T. C., & Gualtieri, F. (2009). New therapeutic maneuver for anterior canal benign paroxysmal positional vertigo. *Journal of neurology*, 256(11), 1851–1855. <https://doi.org/10.1007/s00415-009-5208-1>

- Yacovino, D. A., Zanotti, E., Roman, K., & Hain, T. C. (2021). Square wave manoeuvre for apogeotropic variant of horizontal canal benign paroxysmal positional vertigo in neck restricted patients. *Journal of otology*, 16(2), 65–70.  
<https://doi.org/10.1016/j.joto.2020.10.003>
- Yang, X., Ling, X., Shen, B., Hong, Y., Li, K., Si, L., & Kim, J. S. (2019). Diagnosis strategy and Yacovino maneuver for anterior canal-benign paroxysmal positional vertigo. *Journal of neurology*, 266(7), 1674–1684.  
<https://doi.org/10.1007/s00415-019-09312-1>
- Zuma e Maia F. (2016). New Treatment Strategy for Apogeotropic Horizontal Canal Benign Paroxysmal Positional Vertigo. *Audiology research*, 6(2), 163.  
<https://doi.org/10.4081/audiores.2016.163>